Original Article

Journal of Trauma & Orthopaedic Surgery 2020; April - Jun; 15(2): 16-21

Percutaneous Vertebroplasty for Vertebral Compression Fractures – Practical Tips for Successful Outcome

Sanjeev Motilal Bhandari[1], Siddharth Sanjeev Bhandari[1], Mahadeo Manaji Ghuge[1]

Abstract

Background: *Percutaneous Vertebroplasty (PVP) is an established procedure for vertebral compression fractures (VCF) in elderly due to osteoporosis and vertebral neoplasms. Here we want to share a few practical tips for good results, avoiding potential complications.*

Materials & Methods: *156 patients having 172 VCFs, not responding to conservative treatment, were included in this prospective study from 2012 to 2019. Under local anesthesia, bipedicular entry was taken over 2 mm guide wires using Jamshidi needles. After core biopsy in doubtful aetiology, about 3 to 5 ml of pre-cooled PMMA cement was injected, after contrast injection to check for any leakage. The mean duration of follow-up was 16.2 months, ranging from minimum 12 months to 8 years. Visual analogue scale (VAS) score and Oswestry Disability Index (ODI) were used to evaluate pain relief after PVP.*

Results: *All patients had immediate relief from disabling pain and could be mobilized immediately. VAS Score improved from mean pre-PVP score of 7.8 (range 6-9) to 2.8 (range 0-5) and 3.2 (range 0-6) at 1 week and 1 year postoperative respectively. Similarly ODI improved from 72% to 29% at 1 year follow-up. The complication rate was 6.3%, which included cement leakage (2.5%; n=4), suboptimal cement filling (2.5%; n=4), deep infection (0.64%; n=1) and late cement extrusion in canal (0.64%; n=1).*

Conclusions: *For VCFs, PVP is a cost-effective minimally invasive procedure with immediate pain relief and low incidence of complications. Employing a few modifications in technique, the complications can be further reduced with uniform good results.*

Keywords: *Vertebral fractures, Percutaneous vertebroplasty, Guide wire, Bipedicular technique, Contrast injection*

Introduction

The most common aetiology of painful Vertebral Compression Fractures (VCF) presenting acutely after some trivial trauma like sudden jerk in a vehicle or an insignificant fall in an elderly person, is osteoporosis[1]. Other pathologies weakening the vertebral body, like metastatic secondaries as well as primary neoplasms like myelomas, lymphomas, histiocytomas, haemangiomas etc. may also lead to VCFs. Though VCFs can occur anywhere in the dorsal or lumbar spine, the junctional dorso-lumbar zone is most commonly involved, with around 65 - 70% occurring in D12 or L1.Typically there is no associated neurological compression or neurodeficit in lower limbs.

Many patients respond favourably to conservative management with strict bed rest, analgesics and anti-resorptive drugs, hyperextension braces and physiotherapy measures. But a significant number of patients continue to suffer even after 4 to 6 weeks, with excruciating pain on movements - the typical accordion phenomenon, i.e. severe pain on getting up or lying down - and are severely handicapped even in activities of daily living. For such patients, Percutaneous Vertebroplasty (PVP) offers a minimally invasive surgical technique suitable especially in this elderly population.

Vertebroplasty involves structural reinforcement of a collapsed vertebral body by a filler material like bone or calcium phosphate cement. Historically in 1987, Galibert and Deramond[2] first reported vertebroplasty in a case of vertebral haemangioma, and till 1997, few others[3,4] reported similar good results in various vertebral neoplasms. Jenson et al[5] in 1997 first reported usefulness of vertebroplasty for treating osteoporotic VCFs.

The major advantages of vertebroplasty are that it is usually a percutaneous minimally invasive procedure, can be done under local anaesthesia in this high-risk elderly population and gives immediate relief from the disabling back pain and morbidity[3,6-8]. In addition, core biopsy is possible in cases with doubtful aetiology, and 2 or even 3 vertebral bodies can be injected at the same sitting. Though various complications like dural or nerve root injury by the needle, cement leakage and adjacent level fractures have been described, clinically significant complications are seen in less than 5-6% of cases [3,7,9,10].

Balloon Kyphoplasty (BKP), reported in 2001 by Lieberman et al[11]utilises an inflatable balloon to correct the wedging

[1]Department of Orthopaedics, Dr.V.M.Government Medical College, Solapur.

Address for correspondence:
Dr. Sanjeev Motilal Bhandari
Department of Orthopaedics,
Bhandari Hospital, 146, Railway Lines,
Solapur - 413001 (Maharashtra) India
E-mail: drsmbhandari@gmail.com

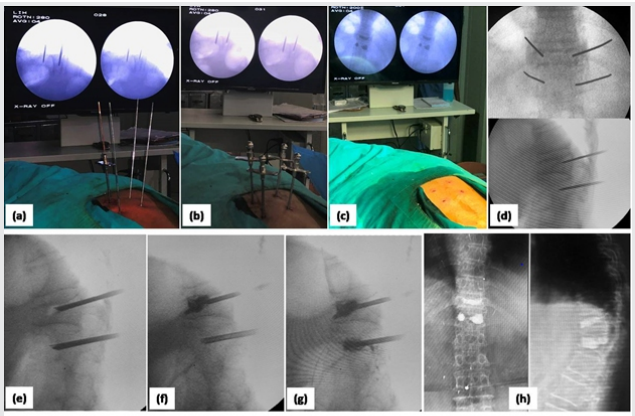

Fig. 1 : Case of PVP at 2 levels - (a) Insertion of 2 mm guide-wires under C-arm guidance ; (b) Insertion of J-needles ; (c) Post-procedure – No suturing required for needle holes ; (d) and (e) Position of guide-wires and J-needles confirmed under C-arm ; (f) and (g) Injecting cement into both the vertebral bodies ; (h) Post-op X-ray

(kyphosis) before cement injection. However, the meta-analysis in 2015 by Shi-Ming et al[12] demonstrated no statistically significant improvement in Visual Analogue Scale (VAS) pain score and Oswestry Disability Index (ODI) score between BKP and PVP, and adjacent level new VCFs were comparable with both these techniques. BKP scored significantly better over PVP only in kyphosis correction and restoration of anterior vertebral body height[10-13]. As PVP is relatively quick and inexpensive[14], it is the most commonly employed procedure at present.

We have performed vertebroplasties since 2004, and in this prospective study since 2012, we have employed a few modifications from past experience to improve the overall outcome. We would like to share these important tips learnt over years to get a good result with minimal complications.

Materials and Methods

We have included 156 cases of VCFs, not responding to

Fig. 3 : Case of IVC at L2 - (a) Pre-op dynamic lateral views with opening up seen on extension ; (b) Post-op X-ray ; (c)-(e) At 4 years follow-up

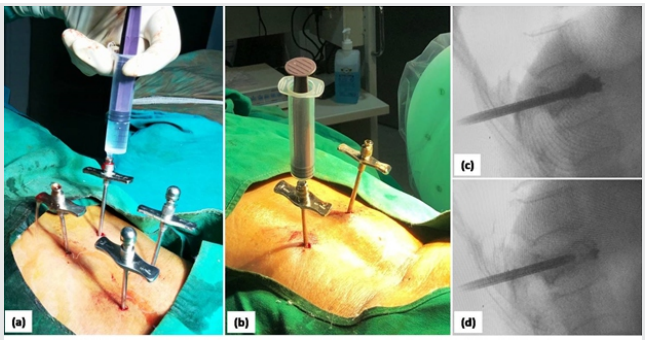

Fig. 2: Technique of bipedicular PVP - (a) Removal of debris by saline irrigation ; (b) and (c) *Omnipaque* injection to check for leakage ; (d) *Omnipaque* washed off with saline

conservative treatment of minimum 4 to 6 weeks and who followed up for one year or more, in this prospective study since 2012. All these patients were treated by percutaneous vertebroplasty at government medical college hospital and a few other centres.

The duration of symptoms was more than 6 weeks in 133 patients (85%), while remaining 23 (15%) were operated between 4 to 6 weeks after injury because of severe unrelenting pain. Two-level vertebroplasty was done in 16 patients – thus total vertebral bodies injected were 172 in 156 patients. Fig.1 shows a case of PVP done at 2 levels (D11 and D12) in the same sitting. None of these patients had any neurological deficit in lower limbs.

Radiographs

AP and dynamic flexion-extension lateral views of the affected region of spine were taken. MRI was done in all cases to rule out neural compression or any other pathology. Intra-Vertebral Cleft (IVC) was present in 66 vertebral bodies (38%), with opening up of cleft seen on extension in X-rays, and fluid shadow in T2W images in MRI. Routine investigations were done with control of co-morbidities pre-operatively.

Except in an obese apprehensive patient and a young girl with cord compression due to D7 haemangioma, the procedure was usually done under local anaesthesia, with a stand-by anaesthetist for monitoring vitals. Pre-procedure analgesia was given along with prophylactic intravenous antibiotic. Prone position on two transverse bolsters – one

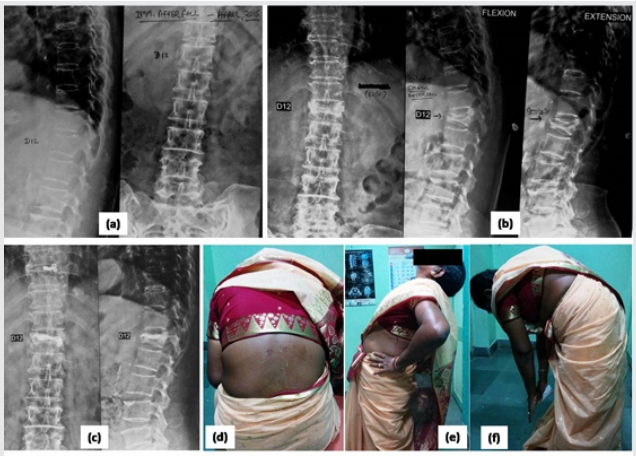

Fig. 4 : Case of VCF due to secondary at D12 - (a) and (b) X-rays immediately after fall and after 5 months ; (c) Post-op X-ray ; (d)-(f) Clinical photos next day after surgery

Fig. 5 : Case of posterior cement leakage in right foramen with temporary neuralgia –
(a) X-ray and (b) clinical picture next day after surgery ;
(c) and (d) At 8 years follow-up – No problems

under the chest and another under the pelvis was given to open up the collapsed vertebra. Lateral C-arm images were taken for level confirmation, as well as for knowing sagittal – i.e. cephalad or caudal trajectory, and skin marking was done accordingly.

Since 2012, we have been doing bipedicular needle passage in the involved vertebra. After painting and draping, C-arm was positioned for AP images, with sagittal inclination as determined by the lateral image, and bilateral pedicle markings were done. Local anaesthetic was infiltrated till the bone. The sharp tip of a routine 2 mm cancellous screw guide-wire was passed in pre-decided cephalo-caudal trajectory to rest at a bony point lateral to the centre of pedicle shadow, to compensate for lateral to medial inclination of guide-wire passage. Usually, it was found to be7° to 10° for dorsolumbar junctional vertebrae and about 15° for the lower lumbar region. The sharp guide-wire was then either pushed manually or gently hammered, while feeling the bony resistance, till it had a good purchase in the pedicle. Similarly, another 2 mm guide-wire was passed in the opposite pedicle.

Now the C-arm was turned for lateral imaging, and sagittal inclination of both wires was checked. The advantage of passing wires, instead of thick needles directly, was that the inclination of either wire could be changed easily at this stage if needed, so as to enter the central cleft of the collapsed vertebra. After correcting the sagittal inclination, both wires were further advanced keeping medial inclination in mind, till their tips breached the tough pedicle-body junction. In case of any doubt, rechecking in AP view was done.

Through stab incisions, a 10 or 11 gauge Jamshidi needle (J-needle) was passed over each guide-wire by twisting movements, keeping its sharp bevelled tip superolaterally to avoid inadvert injury to dura or nerve root below. If needed, a cannulated punch can be used for gentle hammering. Once the needle tip reached posterior body, the guide-wire was removed.

Table1: shows the patient demography and various vertebral levels injected.

Table 1 – Demographic Data			
Variables		**Frequency (n)**	**Percentage (%)**
Age	< 55 years	1	1
	55 – 65 years	36	23
	65 – 75 years	87	56
	>75 years	32	20
Sex	Males	55	35
	Females	101	65
Vertebral level injected	D5 to D10	6	3
	D11	14	8
	D12	71	41
	L1	62	36
	L2	9	5
	L3 to L5	10	6

Core Biopsy

In cases with doubtful diagnosis, one of the needles was passed through a Schanz pin sleeve passed till bone over the guide-wire, and this needle was advanced by 360° circular motion from posterior to anterior 1/3rd of the body through the pathological area. By taking this needle out and pushing with its blunt plunger, a good tissue piece was obtained for histopathological examination. The guide-wire was passed again through the sleeve, the sleeve removed, and J-needle passed again over the wire.

Tips of both the needles were positioned at the junction of anterior and middle 1/3rd of the vertebral body, facing each other. Copious wash was then given by pushing normal saline through one needle, and wash fluid coming out through other needle removed all debris and non-union tissue, creating space for easy pushing of cement later on. It also confirmed proper position of needles in the collapsed body. About 2 to 3 ml of water soluble radio-opaque dye (like Omnipaque) was then pushed through one needle to check for any leakage – especially posteriorly. If any leakage was seen, it was sealed off by passing a small quantity of cement first and allowing it to harden before final cementing. The dye was again washed off by saline. Fig.2 shows this technique of saline irrigation and Omnipaque dye injection for checking leakage.

Cementing

We have used half-dose (20 grams) Polymethyl Methacrylate (PMMA) cement in all cases. For sufficient working time, OR temperature was maintained around 19°C, and cement polymer powder and monomer ampoule were kept in the refrigerator at 4°C overnight. Barium sulphate powder was autoclaved and about half a teaspoonful was added to the polymer powder before mixing, for better radio-opacity of cement during injection.

Bone cement in semi-liquid state was first poured in a 5ml

syringe and an assistant filled multiple 1 ml Tuberculin syringes through the nozzle for cementing. Cement was first pushed through the needle on the side of more collapse, while the second needle acted as a vent for easy spread throughout the body. The J-needle was rotated in all directions for an even spread in the body, and was gradually withdrawn till the posterior 1/3rd of vertebral body. A blunt plunger was used to push the cement stuck in the needle core. Throughout cementing, multiple lateral C-arm shoots were taken, and verbal feedback was obtained from the awake patient, to check for posterior leakage of cement and neural element irritation. The second pedicle needle was used for injecting cement at the end, especially if even spread was not seen in AP imaging. Total 3 to 5 ml of cement was injected in each vertebral body. Both J-needles were removed, final AP and lateral images were taken, and small povidone-iodine dressings were used to seal the needle holes without suturing in most cases. Patient was shifted out after complete hardening of cement.

Post-operatively, patients were allowed to sit up usually after 1 or 2 hours based on pain relief, and discharged the following day after another dose of IV antibiotic at 12 hours. Medical management of osteoporosis was initiated and patients were asked to follow up after 1 week, and then at 3,6 and 12 months post-vertebroplasty.

Results

All 156 patients were followed up for a minimum of 12 months to maximum 8years (mean 16.2 months)after PVP. All these patients, except 1 case of D7 haemangioma, had a bipedicular technique of passage of J-needles over 2 mm guide wires.

Pain Relief and Disability Improvement

It was graded using VAS score and ODI score. The mean VAS score pre-vertebroplasty was 7.8 (range 6 to 9) and ODI was 72% (range 58 - 86%). At 1 week post-operative, VAS score improved to a mean of 2.8 (range 0 to 5) and at 12 months post-operative, it deteriorated slightly to a mean of 3.2. Similarly, ODI score improved to 24% and 29% at 1 week and 12 months post-vertebroplasty respectively. As spondylotic changes were present to a varying extent in this age group, the residual back pain and disability could be explained. The excellent pain relief related to PVP for VCF was maintained in 87.5% patients (14 out of 16) who could be followed up for 2 or more years.

Kyphosis correction

There was a mean correction of 9° in the kyphosis angle (range 0 -18°), which was more pronounced in patients with IVC, due to positional correction in hyperextension. Fig.3 shows a patient of L2 VCF, with IVC seen pre-operatively in dynamic flexion-extension lateral films, and partial correction of kyphosis post-operatively with sustained good results at 4 years follow-up.

Pathological fractures

Four patients had pathological VCFs as confirmed by core biopsy. A 17 years old girl had haemangioma of D7 vertebral body with paraplegia, referred by a neurosurgeon. After open laminectomy and decompression, bone cement was injected through a 12G needle inserted through one pedicle only, which spread evenly in the entire vertebral body, followed by immediate stoppage of profuse bleeding through the needle and anterior to the cord. During the last follow-up at 13 months, there was grade 4 + power in both lower limbs and the girl was walking with support. Two other patients had secondaries and 1 had myeloma - all without cord compression - and there was good palliative pain relief with PVP, followed by further management by oncologist. Fig.4 shows a case of pathological VCF due to secondaries in the D12 vertebral body, operated with PVP.

Complications

No patient had root or dura injury during needle passage.

Cement leakage was seen in only 4 cases (2.5%);3 cases had inconsequential leakage without any clinical untoward effect, while1 case had posterior leakage with temporary sudden burning pain in one lower limb while injecting the cement. After a gap of 10 minutes, remaining 2 to 3 ml of cement was slowly injected, and there was no neurodeficit post-operatively and the patient is totally comfortable at 8 years post-PVP (Fig.5). Owing to the use of bipedicular needles with contrast injection prior to cementing, leakage could be anticipated and two stage cementing could be done if required, as described above.

One patient operated at other centre had deep-seated infection – he had very good pain relief immediately, but presented 6 days post-PVP with severe back pain and morbidity, which settled with 6 weeks of antibiotics.

Late complications like adjacent or non-adjacent level VCFs were seen in only 2 patients out of 16 (12.5%), who could be followed up for 2 years or more. Somehow there was no acute pain or disability due to these new VCFs.

One patient presented 2 years after vertebroplasty with fresh history of fall and paraparesis. X-rays and MRI revealed extrusion of cement in the canal, and he recovered partially to grade 4 power after laminectomy and cord decompression by removing cement pieces.

Discussion

PVP is now widely used to treat painful VCFs due to osteoporosis and other vertebral body pathologies since it was first reported in 1987. There are multiple studies reporting immediate excellent pain relief, which is sustained over a long follow-up period [7,8]. There were a few randomized controlled trials claiming comparable results of vertebroplasty and a sham procedure with placebo[15,16]. But the recent comprehensive review of current concepts published in March 2020 by Hoyt et al[13] compared over a

million patients with VCFs treated with vertebral augmentation and non-surgical management, and reported that the patients receiving augmentation performed significantly better with a decrease in morbidity and mortality.

In our study also, improvement in VAS and ODI at 1 week and 12 months was statistically significant (P<0.001) and comparable to most studies. Kyphosis correction and restoration of anterior vertebral body height by positional correction in hyperextension was more pronounced in patients with IVC, and this was probably the best indication for PVP in our study. Many other authors have reported similar excellent results in VCFs with distinct IVC [7,17,18].

The likely complications include dura or nerve root injury during needle passage, cement leakage - mainly posterior - causing neural element irritation with neurodeficit in lower limbs and adjacent or non-adjacent level new VCFs.

There are conflicting reports about complications in the literature, but none of the studies has more than 10% clinically significant complication rate, though some studies have mentioned higher rates of anterior, lateral or intradiscal cement leakage without any demonstrable post-procedure symptoms [6].

In our study, there was no neural element injury by needle passage. We had 4 cases (2.5%) of cement leakage, with only 1 patient having posterior leakage with temporary neuralgia and no post-operative neurodeficit, and inconsequential leakage in the remaining 3 cases. New VCFs were seen in 2 (12.5%) out of 16 cases which could be followed up for more than 2 years, but none had acute disability because of the new VCFs, and they could be attributed to the underlying osteoporosis rather than the vertebroplasty per se. Many other studies have also demonstrated new VCFs which were comparable to control groups without PVP [7,12].

Overall, we had only 2 (1.3%) clinically significant complications – 1 case of deep-seated infection which settled with IV antibiotics, and another late cement extrusion in spinal canal due to a significant fall, which required open neural decompression for paraparesis. There was partial recovery at last follow-up.

Since 2012, through our own experience, we have modified our technique which has resulted in reducing the complications like cement leakage and achieving good uniform spread of cement with consequential better results. Here we want to enumerate a few useful practical tips for successful PVP –

1. Dynamic flexion-extension X-rays: Important to demonstrate presence of IVC, which is an ideal indication for PVP, and also possible kyphosis correction.

2. Local anaesthesia: Intraprocedure verbal feedback from an awake patient is helpful to avoid neurological complications.

3. Hyperextension position on two transverse bolsters: This opens up the compressed vertebral body, and easy cement injection with some restoration of anterior vertebral body height and correction of kyphosis angle is possible.

4. Use of 2 mm guide-wires for entry: Being smaller in diameter, there are less chances of neural injury during introduction, and if needed, its track can be modified easily as compared to the thicker J-needle. In osteoporotic bones, you can just push it with tactile bony feel owing to its sharp tip, or gently hammer it if required. Chen [19] had also used a K-wire, but only for re-introduction of a second needle in cases of suboptimal cement filling and first needle getting blocked.

5. Bipedicular entry: Though Sun et al [20] have suggested unipedicular approach in their meta-analysis because of less operative time and radiation, we have preferred a bipedicular approach over the last 7 years, as it allows thorough washout of the fluid and debris from collapsed body by saline irrigation, creating space for easy cement injection. The second needle also acts as a vent for easy cement injection without force, and if needed, it can be used for injecting additional cement.

In order to achieve better spread of PMMA cement, Cheng et al[21] have described a technique of Percutaneous Curved Vertebroplasty (PCVP) using a curved injector through unilateral transpedicular needle. We have no experience of that.

6. Core biopsy: Helps by tissue diagnosis in cases of doubtful aetiology of VCF.

7. Constrast injection: It is advisable to inject about 2 to 3 ml of a water-soluble radio-opaque dye and check for any leakage – it is also reported by Toshio et al[9] for VCFs with IVC. If detected, first a very small quantity of cement can be injected to seal the leakage site. After about 10 minutes, the remaining cement can be injected safely.

8. Hypothermic cement cooling: Cement handling time can be increased significantly by keeping both polymer and monomer refrigerated overnight at around 4°C. Chavali et al[22] and Lai et al[23] have demonstrated the same in their studies. They have even done ice bath cooling of mixed cement syringes to increase the handling time upto nearly 2 hours, thus allowing easy cementing at multiple levels.

9. Increasing radio-opacity of cement: By addition of about half a teaspoonful of pre-sterilised barium sulphate powder[9] to the polymer before mixing, easy C-arm monitoring during cementing is possible, thus avoiding leakage.

10. Cementing: Though cement injectors are available, an easy and inexpensive trick is to transfer the cement when it is in a paste-like consistency from a 5 ml syringe nozzle to multiple 1 ml Tuberculin syringes. These can then be used to inject the cement in 1 ml increments each time, pushing with a blunt plunger in between, and monitoring continuously with C-arm images and verbal feedback from the patient.

11. Rotating and withdrawing needle: For even spread of cement, while injecting, bevelled tip of the J-needle should be rotated through 360° and the needle should be withdrawn slowly from anterior and middle 1/3rd junction to middle

and posterior 1/3rd junction of the vertebral body.

Conclusion

PVP has now been widely accepted as a cost-effective modality to treat VCFs due to osteoporosis and other vertebral body pathologies. However its wide use is still jeopardized because of conflicting reports about its utility and possible complications. With our evolving experience with PVP, we have developed certain practical tips for a successful result, with a reduced complication rate, and shared them in this article.

References

1. Heran MK, Legiehn GM, Munk PL. Current concepts and techniques in percutaneous vertebroplasty. Orthop Clin North Am. 2006;37(3):409–434.
2. Galibert P, Deramond H, Rosat P, Le Gars D. Note préliminaire sur le traitement des angiomesvertébraux par vertébroplastieacryliquepercutanée [Preliminary note on the treatment of vertebral angioma by percutaneous acrylic vertebroplasty]. Neurochirurgie. 1987;33(2):166–168.
3. Gangi A, Kastler BA, Dietemann JL. Percutaneous vertebroplasty guided by a combination of CT and fluoroscopy. Am J Neuroradiol. 1994;15(1):83–86.
4. Cotten A, Dewatre F, Cortet B, et al. Percutaneous vertebroplasty for osteolytic metastases and myeloma: effects of the percentage of lesion filling and the leakage of methyl methacrylate at clinical follow-up. Radiology. 1996;200(2):525–530.
5. Jensen ME, Evans AJ, Mathis JM, Kallmes DF, Cloft HJ, Dion JE. Percutaneous polymethylmethacrylate vertebroplasty in the treatment of osteoporotic vertebral body compression fractures: technical aspects. Am J Neuroradiol. 1997;18(10):1897–1904.
6. Cortet B, Cotten A, Boutry N, Flipo RM, Duquesnoy B, Chastanet P, Delcambre B.Percutaneous vertebroplasty in the treatment of osteoporotic vertebral compression fractures: an open prospective study. J Rheumatol. 1999;26(10):2222–2228.
7. Legroux-Gérot I, Lormeau C, Boutry N, Cotten A, Duquesnoy B, Cortet B. Long-term follow-up of vertebral osteoporotic fractures treated by percutaneous vertebroplasty. Clin Rheumatol. 2004;23. 310–317.
8. Klazen CA, Lohle PN, de Vries J, et al. Vertebroplasty versus conservative treatment in acute osteoporotic vertebral compression fractures (Vertos II): an open-label randomised trial. Lancet. 2010;376(9746):1085–1092.
9. Nakamae T, Fujimoto Y, Yamada K, Hashimoto T, Olmarker K. Efficacy of Percutaneous Vertebroplasty in the Treatment of Osteoporotic Vertebral Compression Fractures with Intravertebral Cleft. Open Orthop J. 2015;9:107–113.
10. Lane JM, Johnson CE, Khan SN, Girardi FP, Cammissa FP. Minimallyinvasive options for the treatment of osteoporotic vertebral compression fractures. Orthop Clinics N. America. 33 (2002) : 431 – 38.
11. Lieberman IH, Dudeney S, Reinhardt MK, Bell G. Initial outcome and efficacy of "kyphoplasty" in the treatment of painful osteoporotic vertebral compression fractures. Spine (Phila Pa 1976).2001;26(14):1631–1638.
12. Shi-Meng G,Wen-Juan L,Yun-Mei H, Yin-Sheng W, Mei-Ya H, Yan-Ping L. Percutaneous vertebroplasty and percutaneous balloon kyphoplasty for osteoporotic vertebral compression fracture A metaanalysis. Indian J Orthop2015;49:377-87.
13. Hoyt D, Urits I, Orhurhu V, et al. Current Concepts in the Management of Vertebral Compression Fractures. Curr Pain Headache Rep. 2020;24(5):16.
14. Phillips FM. Minimally Invasive Treatments of Osteoporotic Vertebral Compression Fractures. Spine 2003;28. 15Suppl: S45-S53.
15. Kallmes DF, Comstock BA, Heagerty PJ, et al. A randomized trial of vertebroplasty for osteoporotic spinal fractures. N Engl J Med. 2009;361(6):569–579.
16. Buchbinder R, Johnston RV, Rischin KJ, et al. Percutaneous vertebroplasty for osteoporotic vertebral compression fracture. Cochrane Database Syst Rev. 2018;4(4):CD006349.
17. Kim DY, Lee SH, Jang JS, ChungSK, Lee HY. Intravertebral vacuum phenomenon in osteoporotic compression fracture: report of 67 cases with quantitative evaluation of intravertebral instability.JNeurosurg. 2004 Jan;100(1):24-31.
18. Wu AM, Chi YL, Ni WF. Vertebral compression fracture with intravertebral vacuum cleft sign: pathogenesis, image, and surgical intervention. Asian Spine J. 2013;7(2):148–155.
19. Chen YJ, Chen HY, Lo DF, Chen HT, Hsu HC. Kirschner wire-guided technique for inserting a second needle into inadequately filled vertebrae in vertebroplasty: a technical report. Spine J. 2014;14(12):3025–3029.
20. Sun H, Li C. Comparison of unilateral and bilateral percutaneous vertebroplasty for osteoporotic vertebral compression fractures: a systematic review and meta-analysis. J Orthop Surg Res. 2016;11(1):156.
21. Cheng Y, Liu Y. Percutaneous curved vertebroplasty in the treatment of thoracolumbar osteoporotic vertebral compression fractures. J Int Med Res. 2019;47(6):2424–2433.
22. Chavali R, Resijek R, Knight SK, Choi IS. Extending polymerization time of polymethylmethacrylate cement in percutaneous vertebroplasty with ice bath cooling. AJNR Am J Neuroradiol. 2003;24(3):545–546.
23. Lai PL, Tai CL, Chu IM, Fu TS, Chen LH, Chen WJ. Hypothermic manipulation of bone cement can extend the handling time during vertebroplasty. BMC MusculoskeletDisord. 2012;13:198.

Conflict of Interest: NIL
Source of Support: NIL

How to Cite this Article

Bhandari S M, Bhandari S S, Ghuge M M. Percutaneous Vertebroplasty for Vertebral Compression Fractures – Practical Tips for Successful Outcome. Journal of Trauma and Orthopaedic Surgery. April - Jun 2020;15(2):16-21.