Original Article

Journal of Trauma & Orthopaedic Surgery 2020; April - Jun; 15(2): 1-7

Management of unstable intertrochanteric fracture femur (31a2.2 & 31a2.3) by using dynamic hip screw with modified trochanteric stabilizing plate

Yashwant J Mahale[1], Shankar A Tengale[1]

Abstract

Background: *Intertrochanteric (IT) fractures are most common injuries affecting elderly population. In India more than 2,00,000 IT fractures occur every year. In stable intertrochanteric fractures, Dynamic Hip Screw (DHS) always remains a GOLD STANDARD implant but same results are not reproducible with unstable IT fractures. Standard Trochanteric Stabilizing Plate (TSP) can be used with DHS to minimize postoperative complications in unstable IT fracture femur, however standard TSP does not provide support to posterior or medial fragment in unstable IT fracture specially in AO type 31A2.3 or 31A2.2. Therefore we modified the standard TSP to maintain reduction & provide stability in these unstable IT fractures. The aim of this study is to evaluate the functional & radiological outcome of unstable IT fracture femur in AO type 31A2.3 & 31A2.2 treated by DHS with Modified TSP.*

Material & Methods: *This is a prospective study done at tertiary care centre from December 2016 to November 2018. Total 50 patients with unstable IT fractures having comminution (AO 31A2.3) or vertical split(AO 312.2) fracture of greater trochanter in coronal plane were treated by internal fixation by DHS with Modified TSP. Patients were followed up at 6 weeks, 3 months, 6 months & 1 year for radiological and functional assessment.*

Result: *Out of 50 patients 41 had domestic fall while 9 were injured in RTA. At 1 year follow up, all patients showed union. One patient had shortening of 1 cm & was managed by shoe raise. One patient had superficial infection which was treated successfully by higher oral antibiotics. One patient had 5 mm outward migration of DHS screw at 3 months follow up. All patients were assessed by Harris Hip Score at one year follow up.*

Conclusion: *DHS with Modified TSP fixation in unstable intertrochanteric fracture of femur specially in AO type 31A2.3 or 31A2.2 helps in achieving anatomical reduction, imparts stability, provides an effective technique and has excellent functional and radiological outcomes with minimal complications.*

Keywords: *Unstable IT fracture, DHS, Modified TSP, Functional Outcome.*

Introduction

Intertrochanteric (Pertrochanteric) fractures are most common injuries affecting elderly population. In India more than 2,00,000 Intertrochanteric (IT) fractures occur every year [1]. The intertrochanteric fractures mainly divided into two broad categories as Stable and Unstable types. Stable fractures are those which are undisplaced and with intact posteromedial cortex [2]. Unstable IT fracture accounts for approximately 50 to 60 % of all intertrochanteric fractures [3,4]. The goal of management of intertrochanteric fracture in the elderly patient is to restore safe and efficient mobility while minimizing the risk of medical complications and technical failure. Plating devices are first of its kind of implants used in these type of fractures of which sliding screw plate devices have become standard implant for internal fixation of stable IT fractures. The main complication of using DHS in unstable intertrochanteric fracture is significant medialization of femoral shaft, higher incidence of screw cut-out and shortening with upward migration of greater trochanter [5]. Buttress plates i.e. trochanter stabilizing plate (TSP) act as an adjunct to sliding screw plate devices and aim to restore the lacking lateral buttress in unstable IT fractures. Standard TSP provides reconstruction of trochanteric wall only laterally but does not support posteriorly and medially in unstable IT fracture femur specially when there is comminution or vertical split fracture of greater trochanter in coronal plane. Therefore, we modified this standard TSP in such a way that it will support posteriorly and medially in addition to lateral support. This study was done for the management of unstable IT fracture femur having comminution (31A2.3) or vertical split fracture (31A2.2) of greater trochanter in coronal plane by using dynamic hip screw (DHS) and this Modified TSP to see whether this augmentation gives better results and reduces the complications.

[1]Department of Orthopaedics, ACPM Medical College, Dhule Mahale Accident Hospital, opposite of Ram Wadi, Dhule, MH India

Address for correspondence:
Dr. Shankar A Tengale,
At Post – Kosari, Tal- Jath,
Dist - Sangli – 416403. Mb- 8830220388.
E-mail: shankartengale@gmail.com

Materials & Methods

This is a prospective study done at tertiary care centre from December 2016 to November 2018. Patients with unstable intertrochanteric fractures (AO type 31A2.3 or 31A2.2) were treated by DHS & Modified TSP.



Figure 1: Different Types of TSP

Different types of trochanteric stabilizing plates are available like leaf shaped, star shaped and spoon shaped as shown in Fig. 1.

Modified trochanteric stabilizing plate (modified tsp)

Modifications are additional three curved spikes attached to one side of upper part of spoon shaped standard TSP which runs postero-medially to anchor posterior and medial portion of greater trochanter as shown in Fig.2. This will help to maintain reduction of unstable intertrochanteric fracture femur specially when there is comminution (AO type 31A2.3) or vertical split fracture (AO type 31A2.2) of greater trochanter in coronal plane and will assist to reduce the complications like limb shortening & medialization of femoral shaft, proximal or lateral migration of greater trochanter.

Operative Technique

Approach, guide wire placement, reaming of neck and head, tapping, Richard's screw insertion are same as standard DHS plating procedure.

Application of the DHS plate and Modified Trochanteric Stabilizing plate

Modified TSP was placed inside the sliding plate and under fluoroscopic guidance contouring of proximal or upper part of modified TSP done according to the shape of greater trochanter to prevent upward migration of GT and also to fit TSP on lateral part of greater trochanter and curved spikes to support posteromedially. DHS plate was then slide into shaft of Richard's screw and guide wire was removed. With the impactor, the plate was hammered against cortex of femur. First hole of DHS plate matches with the hole of modified TSP. First cortical screw fixes DHS plate with modified TSP with shaft of femur thus stabilizing DHS with modified TSP.

Figure 2: Modified Trochanteric Stabilizing Plate (Modified TSP)

Table 1: Gender distribution, side of fracture, mode of injury, type of fracture.

Gender Distribution		Side of Fracture		Mode of Injury		Types of Fracture (AO Type)		Total Patients
Males	Females	Left	Right	Fall at home	RTA	31A2.2	31A2.3	
22	28	26	24	41	9	23	27	50

Table 2: Clinical evaluation of unstable fracture at different follow ups:

Clinical Evaluation		Follow up at 6 weeks	Follow up at 3 months	Follow up at 6 months	Follow up at 1 year
Union	No	45	9		
	Yes	5	41	50	50
Deformity	No	50	50	50	50
	Yes				
Limb Length Discrepancy	No	50	49	49	49
	Yes		1	1	1
Infection	No	50	49	50	50
	Yes		1		

Table 3: Radiological evaluation at different follow ups.

Radiological Evaluation		Follow up at 6 weeks	Follow up at 3 months	Follow up at 6 months	Follow up at 1 year
Union	No	45	9		
	Yes	5	41	50	50
GT Position (Displaced/ Non-displaced)	Non Displaced	50	50	50	50
	Displaced				
Position of Implant (In-situ/ Displaced)	In-Situ	50	49	49	49
	Displaced		1	1	1

Derotation screw

An additional 6.5 mm screw is passed parallel to the DHS through the modified TSP to act as an antirotation (derotation) screw while permitting sliding collapse wherever necessary.

Fixation of Greater Trochanter

In some cases the greater trochanter was fixed with fully and partially threaded 6.5 mm CC screw, 4.0 mm CC screw or 4.5 mm cortical screw to prevent upward migration of trochanter and to avoid shortening.

Closure of wound is done in standard method. Postoperative management is similar to DHS procedure. Patients were followed up at 6 weeks, 3 months, 6 months and 1 year clinically regarding hip function, walking ability, deformity and radiologically for union of fracture, position of greater trochanter and implant position. Harris Hip Scoring (HHS) system was used for functional evaluation.

Table 4: HHS score at 1 year follow up.

HHS	Follow up at 1 year	
	Count	Percent
< 70 (Poor)	0	0
70 to 79 (Fair)	1	2
80 to 89 (Good)	5	10
90 to 100 (Excellent)	44	88
Total	50	100

Table 5: Comparision between DHS with TSP & DHS with Modified TSP

STUDY	RESULTS			
	Excellent	Good	Fair	Poor
Ashwin Shetty (2016) [12] DHS & TSP	28%	31%	28%	13%
Ritesh Singh Yadav (2016) [13] DHS & TSP	27%	43%	27%	3%
Dr. D.Thulasi Raman(2018) [14] DHS & Custom made TSP	86%	14%	-	-
Present Study (2018) DHS & Modified TSP	88%	10%	2%	-

Observation and Results

Out of 92 unstable intertrochanteric fractures, 50 were having either comminution (31A2.3) or vertical split fracture (31A2.2) of greater trochanter in coronal plane, managed by DHS with Modified Trochanteric Stabilizing Plate (Modified TSP) fixation. From the clinical notes, x-rays and available data, the information was assembled as follows.

At one year follow up union was observed in 100 % patients.

One cm shortening was observed in 1 patient who was managed by shoe raise.

One patient had superficial wound infection at 3 months follow up which was treated successfully by higher oral antibiotics.

On Radiological examination Union was seen in100% patients at 1 year follow up.

GT position was insitu in all patients. Position of implant was in situ in 100% patients at 6 weeks, while one patient had displaced implant position at 3 months, 6 months and 1 year follow up i.e. 5 mm outward migration of sliding screw.

Average HHS in our study at 1 year follow up was 91.12.

Discussion

Intertrochanteric fracture femur is the most common type of hip fracture in elderly and considered as major challenge to orthopaedic surgeon in view of achieving fracture union, restoration of optimal function in shortest possible time and with minimal complications because in this age group the fracture configuration is comminuted with presence of extensive osteoporosis in unstable intertrochanteric fracture. The aim of management in these fractures is to achieve stable fixation of anatomically reduced fracture, early mobilization, rapid rehabilitation and quick return of individuals to activities of daily living (ADL).

Compression hip screw still remains the GOLD STANDARD for stable intertrochanteric fractures but has high failure rate & complications in unstable intertrochanteric fractures.

The use of DHS in unstable intertrochanteric fracture femur has been associated with excessive collapse, femoral medicalization, lag screw cut out and upward migration of GT.

Addition of standard TSP to DHS supports only lateral wall of greater trochanter and prevents excessive collapse and varus malunion. It does not support posterior or medial wall of greater trochanter and complications like proximal migration of greater trochanter may occur resulting in limb length discrepancy, subsequent shortening of limb and medialization of femoral shaft specially in AO type 31A2.3 or 31A2.2. In these fractures there is difficulty in fixation of comminuted fracture by using standard TSP. Therefore we modified the standard TSP.

Modifications are additional three curved spikes attached to one side of upper part of spoon shaped standard TSP which runs postero-medially to anchor posterior and medial portion of greater trochanter. Contouring of proximal part and additional spikes will help to maintain reduction of unstable intertrochanteric fracture femur specially when there is comminution or vertical split fracture of greater trochanter & reduce the complications like proximal or lateral migration of proximal fragment of greater trochanter, medialization of femoral shaft, implant failure & varus deformity and limb shortening.

Also, the antirotation screw can be inserted through the hole present over superior part of modified TSP and prevent the rotation of proximal fragment. Multiple holes present over modified TSP are used to fix greater trochanter fragment by using 6.5 mm cancellous or 4.5 mm cortical screws if necessary.

Unstable intertrochanteric fracture is still an unsolved problem. Sliding hip system has proved to be the best available implant for osteosynthesis. However DHS has several complications in management of unstable intertrochanteric fracture. Modified TSP is designed to reduce these complications when used with DHS.

In this study an attempt was made to survey, evaluate, document and quantify our results in the management of unstable intertrochanteric fractures by using DHS with modified TSP.

Demography

Most of the patients in present study were from age group of 6th and 7th decade of life. There was a female preponderance in our study with male to female ratio of 1:1.3.

In this study, 41 patients had domestic fall while 9 patients had Road traffic accident (RTA). Left sided unstabble IT fractures were 26 while right sided were 24. In present study, one patient had distal radius fracture and was treated with closed reduction and K-wire fixation.

Clinical Photographs Case 1

Pre Operative X ray - AP view

Pre Operative X ray - Lateral view

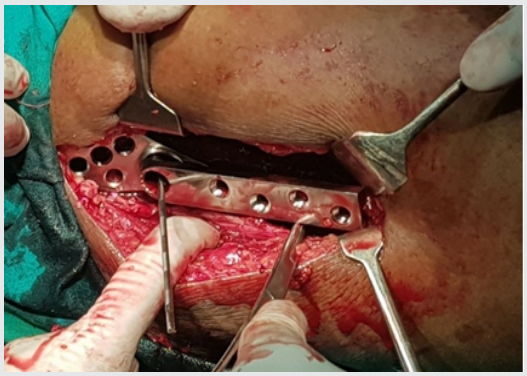

Intra operative clinical image

6 weeks Follow Up X rays – AP View

3 Months follow up X ray – AP View

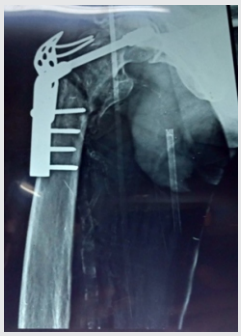

6 weeks Follow Up X rays – Lateral View

3 Months follow up X ray – Lateral View

6 Months follow up X ray – AP View

6 Months follow up lateral view

Functional evaluation at 1 year follow up.

Case 2

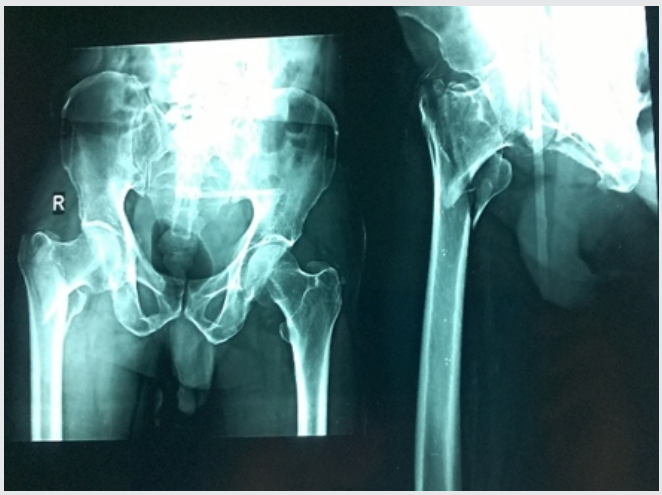

Preoperative X ray – AP & Lateral views

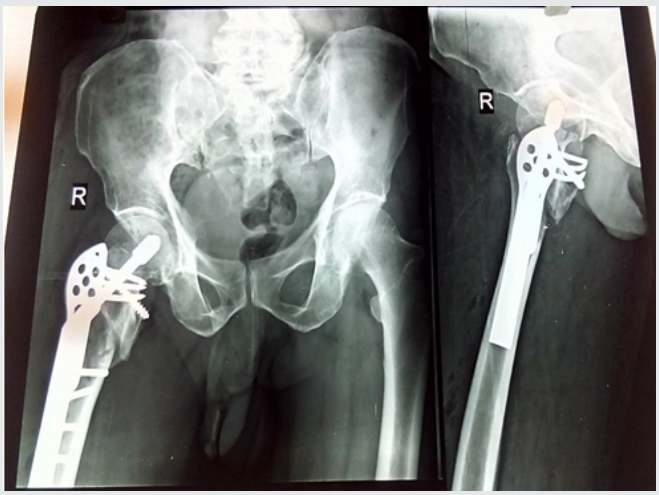

Postoperative X ray – AP & Lateral views

Timing of Surgery

Early surgical intervention is desirable, as it not only avoids the development of complications like hypostatic pneumonia, catheter sepsis, cardio respiratory failure, decubitus ulcers, but also facilitates early rehabilitation and mobilization of patients thereby improving the general well-being of the patients [6,7].

In this study the average duration between trauma and surgery was 10.18 days. This delay was due to referral of patients from primary health centres and also to optimise the patients general condition and to control associated medical comorbidities such as hypertension, diabetes mellitus and anaemia etc.

Duration of Surgery (Operation Time)

The duration of surgery as calculated from the time of incision to skin closure i.e. last suture was counted in each case. In our study, the average duration of surgery for DHS with Modified TSP is 104 minutes, comparable to 89.03 minutes for only DHS fixation [8].

Duration of surgery was more for the initially operated cases but as number of surgery increases, time for surgery decreases rapidly for applying DHS and Modified TSP.

Application of Modified TSP with DHS require only 10-15 minutes extra than DHS.

Blood Loss

DHS with Modified TSP fixation required longer incision and more soft tissue dissection resulting in more blood loss than DHS fixation alone. In our study we measured blood loss by mop count and collection in suction drain (each fully soaked mop containing 70ml blood). In this study, cases operated by DHS with Modified TSP, the average blood loss was 260 ml which is comparable to 253 ml blood loss for DHS fixation alone[9]. Appropriate dissection and avoiding damage to perforator gives a good exposure without much blood loss.

Intraoperative Difficulties

Insertion of the spikes of the Modified TSP with DHS posteromedially to greater trochanter was difficult initially due to soft tissue obstruction. This required more soft tissue release subsequently increasing duration of surgery and blood loss. Also there is difficulty in alignment of hole of the Modified TSP with first hole of the side plate. By practice these difficulties are minimised and DHS with Modified TSP fixation become easy.

Complications

Wound Complications

One patient had superficial wound infection and was treated successfully with higher oral antibiotics for 15 days. This may be attributed to low immunity status of patient as the patient was of asthenic built and belonging to low socioeconomic status & had more soft tissue exposure. Infection rate in our study is 2% which is lower than study carried out by Ujjal Bhakat et al [9] having infection rate of 3.33%.

Post Operative Complications

Screw Migration

It is a phenomenon of characteristic sliding of compression screw to opposite direction during postoperative weight bearing. Normally vertical forces passing from centre of femoral head tends to move the affected hip into varus position as soon as patient is mobilized. This leads to normal sliding of screw achieving expected compression at fracture site.

In our study one patient had outward screw migration of 5 mm, but not having any functional disability and was asymptomatic at 3 months follow up.

Implant (Fixation) failure

Implant failure is due to either screw cut out, or plate breakage in DHS. Failure of DHS plating is up to 4% in unstable intertrochanteric fracture femur [9]. In our study there is no case of implant failure for unstable intertrochanteric fracture femur managed by DHS and Modified TSP.

Shortening

Shortening is one of the main complications that occurred in unstable IT fracture femur treated with DHS only, due to uncontrolled collapse occurred until the head-neck fragment touched the lateral cortex of the femoral shaft. Therefore many fixation devices were used to solve this problem. TSP prevents the additional collapse from lateralization of the greater trochanter and prevent excessive shortening.

In our study we found one patient developed shortening of 1 cm and had difficulty while walking at 3 months follow up. He was treated with shoe raise. Unstable intertrochanteric fracture femur treated by only DHS has 17% average rate of limb shortening more than 2 cm [10] which is higher than treated by DHS and Modified TSP. We found that, Modified TSP when used with DHS reduces the chances of limb shortening. This is because Modified TSP also prevents cephalad migration of greater trochanter.

Deformity

In unstable intertrochanteric fracture femur if, fracture is not reduced anatomically and not fixed appropriately then distal fragment goes into varus due to adductor muscles pull causing deformity. Varus deformity occurs about 25% in patients with unstable IT fracture treated by DHS only [10].

In our study these complications are not seen, as Modified TSP supports postero-medially to greater trochanter in addition to lateral support and thus preventing deformity.

Medialization of Femoral Shaft

It occurs in 20 % in unstable IT fracture treated by DHS alone while it occurs only in 3.5 % treated by DHS with TSP [11].

In our study medialization of femoral shaft was not seen in any patient, as additional spikes in Modified TSP holds greater trochanter in reduced anatomical position and prevents medialization of femoral shaft.

Functional Assessment

In our study we assessed the functional outcome by using Harris Hip Score System. All patients were evaluated clinically and radiologically at the 6 weeks, 3 month, 6 months and 1 year follow ups. At one year follow up excellent results were seen in 88% cases, good in 10% cases, fair in 2% cases.

As this is new device used for unstable intertrochanteric fracture femur there is no published data available to analyse our results. However we compared our results with other studies in which standard TSP is used with DHS.

It is clearly seen from this table that, our results are excellent in 88 % and there are no poor results.

Nowadays PFN is preferred implant for unstable intertrochanteric fracture femur because it has better functional outcome than DHS [9], but DHS with Modified TSP gives comparable results. DHS with Modified TSP is also technically less demanding than PFN.

The cost of the Modified TSP is Rs.700 which is only Rs. 200 excess than standard TSP. Hence Modified TSP when used with DHS is cost effective for the management of unstable intertrochanteric fracture femur specially in AO type 31A2.2 or 31A2.3. It can be used with PFN for the management of unstable intertrochanteric fracture femur for buttressing lateral as well as posteromedial wall of greater trochanter.

Modified TSP can also be usd along with PFN in unstable intertrochanteric fracture to augment stability. PFN with circlage wire and or lag screws has been reported in the literature[15]. Their results are comparable with results of this study.

Limitations

Our study has limitations of small sample size and short follow up. Therefore it needs prospective studies with large number of patients at different institutes with longer follow up, to conclude that Dynamic Hip Screw with Modified TSP is better implant for the management of unstable intertrochanteric fracture femur specially in AO type 31A2.2 or 31A2.3.

Conclusion

In stable intertrochanteric fractures, DHS always remains a GOLD STANDARD implant but same results are not reproducible with unstable intertrochanteric fractures because of complications like excessive medialization of femoral shaft, screw cut-out, limb shortening and proximal or lateral migration of greater trochanter.

DHS with standard TSP does not support posteromedially in unstable intertrochanteric fractures specially for AO type 31A2.2 or 31A2.3. DHS with Modified TSP helps in achieving anatomical reduction, imparts stability, provides excellent results in unstable IT fracture type 31A2.2 or 31A2.3 and assists in reducing above complications.

We conclude that DHS with Modified TSP fixation in unstable intertrochanteric fracture of femur specially for AO type 31A2.2 OR 31A2.3 is an effective technique and has excellent functional and radiological outcomes with minimal complications and early rehabilitation rates.

References

1. Hagord GA, Chaudhary MT, Hussain A, Dynamic hip screw in proximal femur, Indian Journal of Orthopaedics, 1994; 28(2),3-6.
2. Kyle R. F., Gustilo R. B. And Premer R. F. Analysis of six hundred and twenty-two intertrochantenc hip fractures. J.Bone joint(Am). 1979; 61: 216-21.
3. Baumgaertner MR, Curtin SL, Lindskog DM, Keggi JM: The value of the tip apex distance in predicting failure of fixation of peritrochanteric fractures of the hip. J Bone Joint Surg Am 1995;77: 1058-1064.
4. Dieter M. Lindskog, MD, and Michael R. Baumgaertner, MD: Unstable Intertrochanteric Hip Fractures in the Elderly. J. Am Acad Orthop Surg 2004;12:179-190.
5. Babst R, Martinet O, Renner K, et al. Die DHS-Abstützplattefür die Versorgung der instabilenproximalenFemurfrakturen. Schweizer Med Wochenschr 1993;123:566-568.
6. Reska M., Veverkov a L., Divi s P., Konecny J. Proximal femoral nail (PFN) - a new stage in the therapy of extracapsular femoral fractures. SCRIPTA MEDICA (BRNO) June 2006- 79 (2): 115-122.
7. Windoff j, Hollander D A , Hakmi M , Linhart w, - Pitfalls & complications in the use of proximal femoral nail. Lagenbecks arch surg: 2005; feb; 3901(1).
8. Mohammad Faisal and Prithviraj Nistane, Proximal femoral nailing Vs Dynamic Hip Screw in unstable tertrochanteric fracture of femur- a comparative analysis. International journal of biomedical and advance research 2016;7(10) 489-492.
9. Ujjal Bhakat, Ranadeb Bandyopadhayay: Comparitive Study between Proximal Femoral Nailing and Dynamic Hip Screw in Intertrochanteric Fracture of Femur. Open Journal of Orthopedics, 2013, 3, 291-295.
10. Ebrahim Ghayem Hassankhani,MD et al – How to treat the complex unstable intertrochanteric fractures in elderly patients? DHS or Arthroplasty. The archives of bone and joint surgery. ABJS.MUMS.AC.IR: 2014; Sept; Volume 2, No.3.
11. Naiyer Asif, Sohail Ahmad, Owais Ahmad Qureshi et al : Unstable Intertrochanteric Fracture Fixation – Is Proximal Femoral Locked Compression Plate (PFLCP) Better Than Dynamic Hip Screw. Journal of clinical and Diagnostic Research: 2016; Jan.Vol 10(1): RC09-RC13.
12. Ashwin Shetty, Arjun Ballal, Anand Kumar, Sadasivan, Anoop Hedge: Dynamic Hip Screw with Trochanteric Stablization Plate Fixation of

Unstable Inter-Trochanteric Fractures: A Prospective Study of Functional and Radiological Outcomes. Journal of clinical and Diagnostic Research: 2016; Sep, Vol 10(9): RC06-RC08. 10.7860/JCDR/2016/20275.8415.

13. Dr. Ritesh Singh Yadav. A Comparative Study of Trochanteric Stabilizing Plate With Dynamic Hip Screw in Fracture Intertrochanteric Femur With Lateral Wall Comminution. GLOBAL JOURNAL FOR RESEARCH ANALYSIS: 2016; Volume-5, Issue-6,332-334.

14. Dr. D Thulasi Raman, Dr. Arul Vignesh and Dr. Siva Swaminathan : Clinico-radiological results of unstable intertrochanteric fractures treated with custom made Trochanteric stabilizing plate and Dynamic Hip Screw (DHS). International Journal of Orthopaedics Sciences: 2018: 4(3): 308-313.

15. Dr Sunil G Kulkarni, Dr S S Babhulkar, Sujay M Kulkarni, G S Kulkarni, Madhura S Kulkarni, Raviraj Patil: Augmentation of intramedullary nailing in unstable intertrochanteric fractures using cerclage wire and lag screws: a comparative study. Injury. Int. J. Care Injured 48S2(2017) S1-S5.

Conflict of Interest: NIL
Source of Support: NIL

How to Cite this Article

Mahale YJ, Tengale SA. Management of unstable intertrochanteric fracture femur (31a2.2 & 31a2.3) by using dynamic hip screw with modified trochanteric stabilizing plate. Journal of Trauma and Orthopaedic Surgery. April - Jun 2020;15(2):1-7.