

# A prospective study to evaluate clinico-radiological and functional outcomes of Weber type B and Weber type C ankle fractures treated with syndesmotic screw fixation where the screw was removed before starting weight bearing compared to those where the screw was retained in situ indefinitely

Suresh Kripalani<sup>1</sup>, Krishan Kabra<sup>1</sup>, Sunil Kulkarni<sup>1</sup>, Umesh Shelke<sup>1</sup>, Arpit Bavaskar<sup>1</sup>, Areeb Jamal Khan<sup>1</sup>

## Abstract

**Introduction:** It is crucial to adequately stabilize an injury to the distal tibiofibular syndesmosis. A transsyndesmotic screw engaging three cortices from fibula to the tibia is an acceptable method to treat this injury. Surgeons typically tend to remove this screw prior to weight bearing to avoid complications of implant failure and enhance ankle function. There is ongoing contradiction and studies have documented higher rates of wound infections, added morbidity and the costs incurred after routine syndesmotic screw removal. Many studies likewise have advocated against the routine removal of syndesmotic screw. This study aims to compare the functional outcomes in patients with ankle fractures, for whom transsyndesmotic screws were placed and afterwards were either retained or removed.

**Materials and Methods:** Our prospective study sample was chosen from patients of closed malleolar fractures presenting to our Hospital between May 2017 and April 2019. 43 subjects of malleolar fractures were operated with ORIF and tricortical transsyndesmotic screw fixation was done. Syndesmotic screw was removed electively in 20 patients at 12 weeks; and the screw was retained in situ in 23 patients. At 6 months follow-up, functional outcomes of the patients were evaluated as per the rating of the Baird and Jackson criteria.

**Results:** The groups were comparable considering age, gender and follow-up time. Mean age of the patients in the two groups were 41.2 years and 46.78 years respectively. Mean follow up in the two groups were 11.75 and 8.47 months respectively. Overall good to excellent results were seen in >75% patients in both groups. The difference in the incidence of complications in both groups was not significant. However osteolysis was observed around the syndesmotic screws in 18 of 23 patients with retained screws after weight bearing was initiated.

**Conclusion:** There was no significant difference ( $p = 0.74$ ) between functional outcome or range of motion between the groups. Our study does not support routine removal of syndesmotic screws with regard to functional outcome. However it is acknowledged that the risk of syndesmotic screw breakage and failure exists if the screw is retained.

**Keywords:** Ankle fracture, Syndesmosis, Syndesmotic screw, Screw removal

## Introduction

Ankle fractures are amongst the commonly encountered musculoskeletal injuries, and 10% of patients have a associated distal tibiofibular syndesmosis injury necessitating surgical stabilization<sup>(1)</sup>.

The ankle mortise is stabilized by the syndesmotic ligaments by providing strong dynamic support and opposition of the fibula to the fibular notch of the tibia.<sup>(2)</sup> Untreated injury to the syndesmosis leads to abnormal contact pressures in the

ankle joint and development of early arthritis<sup>(3)</sup>. Thus it is vital to diagnose and adequately stabilize an injury to the distal tibiofibular syndesmosis.<sup>(4)</sup>

Intraoperatively to assess syndesmotic stability an external rotation stress or a lateral distraction force is applied by placing the bone hook on the fibula in an attempt to separate the fibula from the tibia. On AP and Mortice view radiographs of the ankle, this may demonstrate an increase in tibiofibular clear space, decreased tibiofibular overlap and increased medial clear space, which would indicate injury to the syndesmotic ligaments.<sup>(5)(2)</sup>

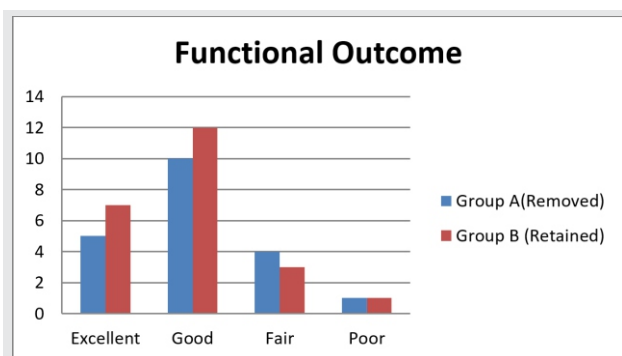
The surgical motive is to keep the structures in their correct position so that the ligaments can heal properly.<sup>(6)</sup> Recent studies have reasoned to place a syndesmotic screw at 2.0 cm above tibiotalar joint as acceptable method to stabilize the syndesmotic diastasis.<sup>(7)(5)</sup>

There is lack of consensus in the recent literature pertaining to removal of syndesmotic screws prior to weight bearing. The

<sup>1</sup>Department of Orthopaedics, P.G.I. Swasthiyog Prathishthan  
Miraj, India – 416410

### Address for correspondence:

Dr. Krishan Kabra,  
Department of Orthopaedics, P.G.I. Swasthiyog Prathishthan  
Miraj, India – 416410  
Email: kabrakrishan05@gmail.com



**Figure 1:** Comparison of functional outcomes in Group A (Screw Removed) and Group B (Screw Retained)

presence of the screw may limit the dynamic motion of the fibula during walking, thereby some studies advocate removal of screws to restore physiological biomechanics of the syndesmosis and improve function.(8)(5) There is difference in opinions among authors if there is correlation between loss of radiographic syndesmotic parameters and removal of syndesmotic screw. However it is agreed that the ankle mortise remained intact whether the syndesmotic screws were removed, were loosened or broken, or remained solid.(9)(10)

In a study by Qamar and coworkers it was suggested that although routine removal of syndesmotic screws is not required, surgeons electively remove screws to avoid the possibility of hardware irritation or reduced range of motion after four to six months.(11)

On the other perspective in a study by Hamid et al it was related that there was no difference in clinical outcome of patients with intact or removed syndesmotic screws.(12) A study by Andersen et al documented higher rates of wound infections after routine syndesmotic screw removal. They related that the patients with postoperative infection reported more pain and were lesser satisfied with their ankle compared to those without infection.(13) In this study we aimed to compare the functional outcomes in adult patients with ankle fractures, for whom syndesmotic screws were inserted and were either subsequently retained or removed.

### Materials & Methods

From May 2017 to April 2019, total of 43 subjects of malleolar fractures undergoing ORIF at our Institute, were studied prospectively. This study was approved by the ethics committee of our hospital, and informed consents were obtained from patients or their legal relatives. All the adult patients of closed malleolar fractures were eligible for the study, cases which did not prove syndesmotic instability during intraoperative stress testing were not included in the study.

Affected ankle and tibia AP and lateral radiographs were taken. The fractures were then classified as per the Weber's classification. Patients were given below knee POP slab with strict limb elevation till the time of surgery.

**Table 1:** Distribution of patients according to their demographic and clinical characteristics

	Group A (Screw Removed)		Group B (Screw Retained)	
<b>Total patients</b>	<b>20</b>		<b>23</b>	
<b>Age Distribution</b>	<b>n</b>	<b>%</b>	<b>n</b>	<b>%</b>
<b>20-29</b>	3	15	2	8.695652
<b>30-39</b>	7	35	6	26.08696
<b>40-49</b>	2	10	6	26.08696
<b>50-59</b>	6	30	5	21.73913
<b>60-69</b>	2	10	4	17.3913
<b>Mode of Injury</b>				
<b>RTA</b>	7	35	6	26.08696
<b>Fall</b>	11	55	14	60.86957
<b>Sports</b>	2	10	3	13.04348
<b>Side affected - Right</b>	13	65%	17	73.91%
<b>Fracture Pattern</b>				
<b>Bimalleolar</b>	12	60	13	56.52174
<b>Lateral Malleolar</b>	3	15	2	8.695652
<b>Trimalleolar</b>	5	25	8	34.78261
<b>Webers Classification</b>				
<b>B</b>	13	65	16	69.56522
<b>C</b>	7	35	7	30.43478

### Operative Procedure

Spinal anesthesia was administered to all patients. Second generation Cephalosporins Antibiotics were administered at the time of induction of anesthesia.

Under all aseptic surgical precautions, as per the standard approaches, Lateral malleolar fixation was done in 43 cases. At our institute for reduction of the distal tibio-fibular syndesmosis, a large bone reduction clamp was used to maintain compressive force between fibula and tibia after reducing the fibula by putting it back into the fibular notch of the tibia, evaluating the alignment and reduction via fluoroscopy. During screw insertion the ankle joint was kept in neutral to mild dorsiflexion position at our institute. Fixation involved a three cortex purchase from the fibula to the tibia using 3.5mm cortical screw 2cm above the tibiotalar joint line.

Medial malleolus fixation was done in 38 patients. Posterior malleolar fracture was noted in 13 cases. The posterior malleolar fracture was fixed using the standard approach and mode of fixation decided intraoperatively.

In all cases, tibio talar articular congruence was restored < 1 mm of normal, confirmed via fluoroscopy. All the patients were operated under tourniquet control. The duration of surgery varied from 30 to 80 minutes. IV Antibiotics were administered for 2 days postoperatively. Radiological evaluation was done in the postoperative period which included both Anteroposterior and Lateral views. Regular daily dry dressings were done. Patient was mobilized on the

**Table 2:** Comparison of functional outcomes and complications between Group A (Screw Removed) and Group B (Screw Retained).

	Group A (Screw Removed)		Group B (Screw Retained)		p-value
Demographic Variables	n	%	n	%	
Mean age	41.2+/-13.16		46.78+/-15.18		<b>0.355</b>
Males	16	80%	17	73.91%	
Females	4	20%	6	26.09%	
<b>Time of follow up [months]</b>					
Mean (Range)	11.75 (6-20)		8.47 (6-18)		<b>0.287</b>
<b>Functional Outcome [Baird and Jackson Ankle score]</b>					
Excellent	5	25.00%	7	30.40%	
Good	10	50.00%	12	52.20%	
Fair	4	20.00%	3	13.00%	
Poor	1	5.00%	1	4.30%	
<b>Range of Motion(plantar flexion- dorsiflexion arc)</b>					
30-39	4	20.00%	3	13.00%	<b>0.165</b>
40-49	2	10.00%	3	13.00%	
>50	14	70.00%	17	73.90%	
<b>Complications</b>					
Superficial skin infection	3	15.00%	3	13.00%	<b>0.553</b>
Ankle stiffness	2	10.00%	3	13.00%	
Syndesmotic screw breakage	0	0.00%	1	4.30%	

first postoperative day, non-weight bearing on the affected leg with the help of walker. Patients were discharged on the fifth day on an average.

The patients were followed up at 2nd week, 6th week, 3rd month and 6th month. Sutures were removed at 2 weeks follow up in the outpatient clinic. Posterior slab removed same day, and range of motion of ankle started but patients were advised to continue non weight bearing ambulation with a walker for a period of four weeks. Check x rays were done at 6weeks. Signs of healing and status of the joint was noted.

At 12 weeks follow up, syndesmotic screw was electively removed in 20 patients after informed consent. Under all aseptic precautions, parts painted and draped, under local anesthesia syndesmotic screw was removed with stab incision. Single dose of intravenous antibiotic was given perioperatively, followed by 5 days of oral antibiotics. Patients were advised partial weight bearing according to the xray picture and suture removal after 15 days.

At 6 months follow-up, functional outcome of the patients were evaluated as per the rating of the Baird and Jackson criteria which included objective criteria, subjective criteria and Radiological evaluation.

#### Statistical Analysis

All statistical analyses were performed using SPSS and a threshold of  $p < 0.05$  was set for statistical significance. The data are presented as n (%) or mean and standard deviation and was analysed by chi-square test and Student's t test, depending on distribution.

#### Results

During the study period 43 patients with ankle fractures were operated and underwent syndesmotic screw fixation in our department. Of all the patients, syndesmotic screw was electively removed in 20 patients (Group A) at 12 weeks; and the screw was retained in situ in 23 patients (Group B).

Mean age of the patients in group A and group B were 41.2 years and 46.78 years respectively. There was no difference in the age distribution between the two groups ( $p=0.35$ ). Male predominance was seen in present study with, 33 males (76.74%) to 10 (23.25%) females. Bimalleolar fractures (25) were more common, followed by trimalleolar (13) and lateral malleolus fractures (5). Majority of the fractures belonged to Weber type B (29), while 14 were Weber type C. There were 30 (69.77%) patients with right malleolar fractures and 13 (30.23%) patients with left malleolar fractures. In our study, 25 (58.14%) patients sustained injury following road traffic accidents (RTAs), 13 (30.23%) sustained injury following fall and 5 (11.63%) patients sustained injury while playing sports. (Table 1)

Average follow-up duration in group A was 11.75 months and 8.47 months in group B ( $p=0.28$ ). Functional outcome was assessed by using Baird and Jackson score. At the end of 6 months, in group A 5 (25.0%) patients had excellent outcome, 10 (50.0%) had good results, 4 (20.0%) patients had fair outcome while 1 (5.0%) had poor results. At the end of 6 months, in Group B 7 (30.4%) patients had excellent outcome, 12 (52.2%) had good results, 3 (13.0%) patients had fair outcome while 1 (4.3%) had poor results. (Table 2) Mean Ankle scores were  $92 \pm 5.33$  and  $92.59 \pm 5.64$  in group A and group B respectively. There was no significant difference ( $p = 0.74$ ) between the scores in both groups. (Figure 1) The range of motion (plantar flexion-dorsiflexion) arc was more than  $50^\circ$  in 70% patients in group A and in 73.9% patients in group B. This difference was not statistically significant ( $p=0.165$ ). There were no cases of intra operative complications in both the groups. In group A post-operative complications were noted to be 3 cases (15%) had superficial skin infections and 2 cases (10%) had Ankle stiffness. In Group B, 3 cases (13%) had superficial skin infections, 3 cases (13%) had Ankle stiffness and in 1 patient (4.3%) screw breakage was noted. The difference in the incidence of complications in both groups was not significant ( $p>0.05$ ). No evidence of widening of the syndesmosis was noted on follow up radiographs even on commencing weight bearing. However osteolysis was observed around the syndesmosis screws in 18 of 23 patients with retained screws (group A) after weight bearing was commenced. No osteolytic changes were noted in the group B. Delayed diastasis or loss of reduction on follow up radiographs after screw removal was not appreciated in any of the patients from Group B. Whilst the accuracy of reduction can only be judged by CT, it was not a primary objective of our study. No radiographic evidence of osteoarthritis in both the group of patients. This could be due to the relatively short period of follow-up in the study.

### Discussion

Syndesmosis screw fixation is a proven and popular means of treatment for syndesmosis diastasis. (7)(14)(15) The

current literature is of insufficient quality and lack of consensus exists to be able to draw definitive conclusions in context to removal of the syndesmosis screw. (16) A study by Schepers et al proposed favourable functional outcome of acute syndesmosis injuries treated with a syndesmosis screw. The functional outcome is influenced by patient and fracture characteristics. (17) Majority of ankle fractures occur in young adults which can be related to more outdoor activity. (18) The age distribution in present study is in accordance to the previous literature. 37 out of 43 patients were from age group 21 to 59 years in this study.

A survey by Bava and colleagues analysed the typical practice of surgeons in treatment of distal tibiofibular diastasis and also evaluated varied practice of size of the screw used, number of screws and number of cortices engaged. Their survey indicated that the use of 3.5-mm screws engaging 4 cortices routinely removed in the operating room at 3 months was most commonly practiced, 1 or 2 screws used. (14) In a review on operative aspects of syndesmosis injury by Michel P.J. and van den Bekerom et al. they reported that the larger screws caused more discomfort and the benefit of using 3.5 mm screws included a less prominent screw head.. This study found that quadricortical fixation using two screws was more rigid causing more stiffness in comparison three cortices engaged with a single syndesmosis screw. (5)

Removal of the syndesmosis screw prior to weight bearing has been advocated by many authors and is typically practiced. (19)(14) Higher rates of wound infection and complications have been related to syndesmosis screw removal. (13)(20) Secondly there are financial costs incurred both by the institution and the patient for a second surgery and associated morbidity which may not be always necessary. This policy of routine removal thereby becomes an avoidable expenditure. A study by Tucker et al reflected that routine removal of the syndesmosis screw is not necessary. This is in keeping with several other studies in the reported literature. (12)(16) They stated that the screw should remain in situ, and removal should only be indicated in symptomatic patients with persistent hardware complaints. (21)

With the advent of bioabsorbable implants the whole debate pertaining to syndesmosis screw removal gets subdued. If bioabsorbable screws are used for transsyndesmosis screw fixation, the need for a second removal surgery is obviated. Several recent studies have documented no difference in any of the outcome measurements between the bioabsorbable screw and the conventional metal screw. (22)(23)(24) It is evident that bioabsorbable screws have advantages but incur higher costs.

We acknowledge that there are few limitations to this study. The allotment of the patients to the groups was not randomized. Patient factors, patient compliance and adherence to physiotherapy may have influenced the functional outcomes. We also accept that our study

population is small and relatively less duration of patient follow up. Lastly, this being a single centre study, the conclusions might not be generalizable to other surgical centres.

### Conclusion

The difference between functional outcomes of patients in which screw was removed compared to those in which screw

was retained was not significant ( $p=0.73$ ). The presence of complications hampered the functional outcome in our study. We found no statistically significant difference in the incidence of complications between the two groups ( $p=0.55$ ). Our study does not support routine removal of syndesmotom screws with regard to functional outcome. However it is acknowledged that the risk of syndesmotom screw breakage and failure exists if the screw is retained.

### References

- Schepers T, Van Zuuren WJ, Van Den Bekerom MPJ, Vogels LMM, Van Lieshout EMM. The management of acute distal tibio-fibular syndesmotom injuries: Results of a nationwide survey. *Injury*. 2012;43(10):1718–23.
- Zalavras C, Thordarson D. Ankle syndesmotom injury. *J Am Acad Orthop Surg*. 2007;15(6):330–9.
- Lin C-F, Gross MT, Weinhold P. Ankle Syndesmosis Injuries: Anatomy, Biomechanics, Mechanism of Injury, and Clinical Guidelines for Diagnosis and Intervention. *J Orthop Sport Phys Ther*. 2006;36(6):372–84.
- Weening B, Bhandari M. Predictors of functional outcome following transsyndesmotom screw fixation of ankle fractures. *J Orthop Trauma*. 2005;
- M.P.J. van den B, M. H, H.W. B, C.N. van D. Operative aspects of the syndesmotom screw: Review of current concepts. *Injury* [Internet]. 2008;39(4):491–8. Available from: [http://www.embase.com/search/results?subaction=viewrecord&from=export&id=L50080491%5Cnhttp://dx.doi.org/10.1016/j.injury.2007.11.425%5Cnhttp://sfxhosted.exlibrisgroup.com/dal?sid=EMBASE&issn=00201383&id=doi:10.1016%2Fj.injury.2007.11.425&title=Operative+](http://www.embase.com/search/results?subaction=viewrecord&from=export&id=L50080491%5Cnhttp://dx.doi.org/10.1016/j.injury.2007.11.425%5Cnhttp://sfxhosted.exlibrisgroup.com/dal?sid=EMBASE&issn=00201383&id=doi:10.1016%2Fj.injury.2007.11.425&title=Operative+syndesmosis.)
- de-las-Heras Romero J, Alvarez AML, Sanchez FM, Garcia AP, Porcel PAG, Sarabia RV, et al. Management of syndesmotom injuries of the ankle. *EFORT Open Rev*. 2017;
- McBryde A, Chiasson B, Wilhelm A, Donovan F, Ray T, Bacilla P. Syndesmotom screw placement: A biomechanical analysis. *Foot Ankle Int*. 1997;
- Huber T, Schmoelz W, Bölderl A. Motion of the fibula relative to the tibia and its alterations with syndesmosis screws: A cadaver study. *Foot Ankle Surg*. 2012;
- Jordan TH, Talarico RH, Schuberth JM. The radiographic fate of the syndesmosis after trans-syndesmotom screw removal in displaced ankle fractures. *J Foot Ankle Surg*. 2011;
- Gennis E, Koenig S, Rodericks D, Otlans P, Tornetta P. The fate of the fixed syndesmosis over time. *Foot Ankle Int*. 2015;
- Qamar F, Kadakia A, Venkateswaran B. An Anatomical Way of Treating Ankle Syndesmotom Injuries. *J Foot Ankle Surg*. 2011;
- Hamid N, Loeffler BJ, Braddy W, Kellam JF, Cohen BE, Bosse MJ. Outcome after fixation of ankle fractures with an injury to the syndesmosis. *J Bone Joint Surg Br*. 2009;
- Andersen MR, Frihagen F, Madsen JE, Figved W. High complication rate after syndesmotom screw removal. *Injury*. 2015;
- Bava E, Charlton T, Thordarson D. Ankle fracture syndesmosis fixation and management: the current practice of orthopedic surgeons. *Am J Orthop (Belle Mead NJ)*. 2010;
- Kaye RA. Stabilization of ankle syndesmosis injuries with a syndesmosis screw. *Foot Ankle*. 1989;
- DIngemans SA, Rammelt S, White TO, Goslings JC, Schepers T. Should syndesmotom screws be removed after surgical fixation of unstable ankle fractures? a systematic review. *Bone and Joint Journal*. 2016.
- Schepers T, Van Der Linden H, Van Lieshout EMM, Niesten DD, Van Der Elst M. Technical aspects of the syndesmotom screw and their effect on functional outcome following acute distal tibiofibular syndesmosis injury. *Injury*. 2014;
- Court-Brown CM, Caesar B. Epidemiology of adult fractures: A review. *Injury*. 2006.
- Bell DP, Wong MK. Syndesmotom screw fixation in Weber C ankle injuries-should the screw be removed before weight bearing? *Injury*. 2006;
- Schepers T, Van Lieshout EMM, de Vries MR, Van der Elst M. Complications of Syndesmotom Screw Removal. *Foot Ankle Int*. 2012;
- Tucker A, Street J, Kealey D, McDonald S, Stevenson M. Functional outcomes following syndesmotom fixation: A comparison of screws retained in situ versus routine removal - Is it really necessary? *Injury*. 2013;
- Sun H, Luo CF, Zhong B, Shi HP, Zhang CQ, Zeng BF. A prospective, randomised trial comparing the use of absorbable and metallic screws in the fixation of distal tibiofibular syndesmosis injuries: Mid-term follow-up. *Bone Jt J*. 2014;
- van der Eng DM, Schep NWL, Schepers T. Bioabsorbable Versus Metallic Screw Fixation for Tibiofibular Syndesmotom Ruptures: A Meta-Analysis. *Journal of Foot and Ankle Surgery*. 2015.
- Xie Y, Cai L, Deng Z, Ran B, Hu C. Absorbable Screws Versus Metallic Screws for Distal Tibiofibular Syndesmosis Injuries: A Meta-Analysis. *Journal of Foot and Ankle Surgery*. 2015.

Conflict of Interest: NIL  
Source of Support: NIL

### How to Cite this Article

Kripalani S, Kabra K, Kulkarni S, Shelke U, Bavaskar A, Khan AJ. A prospective study to evaluate clinico-radiological and functional outcomes of Weber type B and Weber type C ankle fractures treated with syndesmotom screw fixation where the screw was removed before starting weight bearing compared to those where the screw was retained in situ indefinitely. *Journal of Trauma and Orthopaedic Surgery*. Apr-Jun 2019;14(2):14-18.