Original Article

Journal of Trauma & Orthopaedic Surgery 2018; Jan- March; 13(1):10-12

Comparative Study of Arthroscopic Anterior Cruciate ligament reconstruction by Bone Tendon Bone Method and Semitendinosus Method

P G Kulkarni[1], Sahil Bhagat[1], Rishi Doshi[1], Keyur Patel[1]

Abstract

Introduction: *Anterior cruciate ligament (ACL) tear is one of the leading knee injuries throughout the world. The incidence of Anterior Cruciate Ligament tear has increased in the general population with the rise of participation in Sports. The expectations of young male and female professional and recreational athletes has also risen as they expect to return to the preinjury activity levels. Number of patients undergoing ACL reconstruction has risen and results have also improved because of advancement in arthroscopy and arthroscopic equipments. The ACL prevents anterior translation of tibia and is important in counteracting rotation and valgus stress. ACL deficiency leads to knee instability. This result in recurrent injuries and increased risk of intra-articular damage, especially the meniscus(4,5). The goals of the ACL reconstruction are to restore stability to the knee; allow the patient to return normal activities earliest, including sports activities; and to delay the onset of osteoarthritis with associated repeated injuries to the articular cartilage and loss of meniscal function. Materials & Method: 40 patients with ACL tear will be considered in this study; 20 of bone tendon bone method ;and 20 of semitendinous method . Results: Mean age for Group I was 33.65 + 9.41 years .Mean age for Group II was 25.75 + 6.29 years. Functional outcome was assessed by IKDC .The mean p values of IKDC at 6weeks, 3 months and 6months were 0.6, 0.57 and 0.78 respectively. As all the values are more than 0.05 which shows no statistical significant difference.Conclusion: Bone tendon bone graft goes for bone to bone healing which is proved beyond doubt and given excellent physiological fixation. Semitendinosus graft is a more cosmetic alternative reflecting almost similar post operative success.There is no difference in functional outcome of bone tendon bone and semitendinosus method.*

Keywords: *Bone tendon bone ,semitendinosus, ACL tear.*

Introduction

Anterior cruciate ligament (ACL) tear is one of the leading knee injuries throughout the world. The incidence of Anterior Cruciate Ligament tear has increased in the general population with the rise of participation in Sports. The expectations of young male and female professional and recreational athletes has also risen as they expect to return to the preinjury activity levels. Number of patients undergoing ACL reconstruction has risen and results have also improved because of advancement in arthroscopy and arthroscopic equipments.The use motorbikes increased the incidence of ACL tear in RTA in India and China.The weight of motorbikefalling on medial aspect of the knee ,resulting in twisting in knee and ACL injury. Anterior cruciate ligament (ACL) is an intra-articular structure present in the central complex of the knee joint which along with other structures in and around knee joint controls, limits motion and maintains static and dynamic equilibrium of knee joint[1,2] Anterior cruciate ligament (ACL) tear is the most frequent serious ligamentous injury to the knee joint[1,3]. The ACL prevents anterior translation of tibia and is important in counteracting rotation and valgus stress. ACL deficiency leads to knee instability. This result in recurrent injuries and increased risk of intra-articular damage, especially the meniscus [4,5]. The goals of the ACL reconstruction are to restore sta bility to the knee; allow the patient to return normal activities earliest, including sports activities; and to delay the onset of osteoarthritis with associated repeated injuries to the articular cartilage and loss of meniscal function. During the past decade arthroscopically aided techniques have been an accepted method of ACL reconstruction. The anterior cruciate ligament (ACL) serves an important stabilizing and biomechanical function for the knee joint. Rupture of the ACL leads to abnormal kinematics and predisposes the joint to degenerative changes.Several authors agree that in the young and active patient surgical reconstruction of the torn ACL is the treatment of choice, which allows the patient to their previous activity level. Moreover reconstruction of a torn ACL prevents meniscal and secondary chondral lesions. Anterior knee instability associated with rupture of ACL is a disabling clinical problem in general and especially in athletic individuals. ACL has a poor capacity of recovery. The need for surgical treatment of ACL injuries arises because, untreated complete injury to the ligament leads to progressive symptomatic instability leading to recurrent injury and damage to the menisci and articular cartilage thus resulting in early osteoarthritis [6-8]. Arthroscopic guided ACL Reconstruction (ACLR) has multiple advantages

[1]Department of Orthopaedics , Dr D . Y . Patil Medical College, Kolhapur, Maharashtra, India

Address for correspondence:
Dr P G Kulkarni Professor of Orthopaedics
Dr D Y Patil Medical College , Kolhapur

Email: drprakashgkulkarni@gmail.com

Figure 1: Positioning and marking of landmarks.

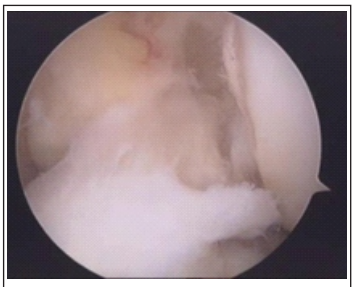

Figure 2: Diagnostic arthroscopy

Figure 3: semitendinosus graft

over open ACLR[8]. Numerous authors have described successful reconstruction of ACL (ACLR) with use of autografts (e.g. Patellar tendon, hamstring tendons, distally based ilio tibial band (ITB), fascia late etc) and allografts (e.g. Achillis tendon, tibialis anterior, patellar tendon, hamstring tendons etc)[8-12] Surgical method of reconstruction of the torn anterior cruciate ligament can be divided into three broad categories

1. The intra-articular reconstruction
2. The extra–articular reconstruction
3. Combined intra and extra articular reconstruction.

With advances in arthroscopy and surgical techniques intra–articular reconstruction of anterior cruciate ligament is preferred as it is more anatomical, accurate and effective with less morbidity .The Bone-Patellar tendon-Bone and hamstring graft are the most commonly used autograft for reconstruction[13-17] The bone–patellar tendon–bone graft usually is an 8- to 11-mm-wide graft taken from the central third of the patellar tendon, with its adjacent patella and tibial bone blocks. This graft's attractive features include its high ultimate tensile load (approximately 2300 N), its stiffness (approximately 620 N/mm), and the possibility for rigid fixation with its attached bony ends and early incorporation. There has been an increase in the popularity of hamstring tendons as autografts for ACL reconstruction, which can avoid harvest site morbidity. Hamstring autografts are made with the semitendinosus tendon, either alone or accompanied by gracilis tendon for a stronger graft. Advantage of semitendinosus graft is small incision and less anterior knee pain. The main disadvantages of the BTB technique are the donor site morbidity and occasional pre patellar pain. Problems with the use of the semitendinosus and gracilis (STG) technique, on the other hand, are late progressive knee laxity, the development of flexion deficit and increased risk of tunnel widening.Weakness in internal rotation of tibia leading to inability to kick the ball in Soccer players. In our study we have compared the results of Arthroscopic ACL reconstruction using semitendinosus and bone tendon bone graft. This comparison is needed to achieve anatomical, structural, mechanical and physiological restoration of utmost important ligament in the knee.

Material and methods

Between May 2014 to May 2016 all patients who underwent arthroscopic assisted ACL reconstructions using the bone-patellar tendon-bone autograft and semitendinosus graft in the Department of Orthopaedics, D.Y.Patil Medical College & Hospital, Kolhapur, Maharashtra is the material in our study.

No. of Cases: 40 cases

Duration of study: May 2014 to May 2016.

Inclusion Criteria

All patients with ACL Tear

1) Who are in the age groups between 18 to 50 years.

2) With no evidence of clinical and radiological degenerative change in the knee joints.

Exclusion criteria included

1. Children with open growth plate.
2. Patients managed conservatively for other medical reasons..
3. Previous ligamentous injury in the same knee joint.
4. Bilateral ACL injury.
5. Associated fractures of the lower limbs.
6. Neurovascular compromise
7. Non-compliant patient

Figure 4: Graft Preparation

Figure 5: Aiming guide-wire in the femoral footprint

Method:

It is a prospective cohort study. 40 patients will be considered in this study; 20 of bone tendon bone method;and 20 of semitendinous method. The

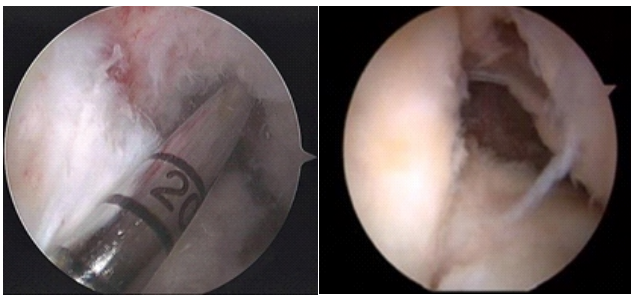

Figure 6: Femoral Tunnel drilling through anteromedial portal

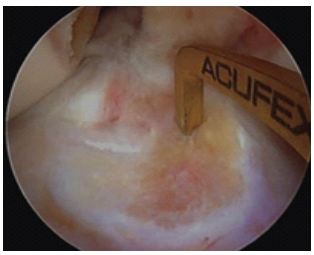

Figure 7: Tibial elbow aimer kept in line with anterior horn of lateral meniscus and appro. 7mm anterior to PCL

Figure 8: Endobutton

patients history will be initially taken, followed by thorough clinical examination especially for the affected knee. Then after coming to clinical provisional diagnosis, all other investigations like Blood investigations, X rays, most important MRI findings and other requiring investigations will be carried out. After the operative procedure, the patients will be assessed postoperatively and examined thoroughly on regular intervals. The range of movements, anterior knee pain, donor site morbidity will be assessed. This will be based on IKDC score.

Evaluation of Results

All the patients were evaluated periodically at 6 weeks, 3 months, 6 months. The standard protocol of IKDC is used for evaluation of the results of the surgery during follow up. At each follow up along with subjective evaluation, the following clinical examinations were also done.

- Ligament laxity was assessed using Anterior Drawer Test, Lachman Test and pivot shift test.
- Range of motion of the operated knee was noted and compared with the opposite knee.
- Knee extension or straight leg raising (quadriceps power) was assessed.

Surgical Technique

1. Bone tendon bone acl reconstruction

The anterior cruciate ligament was reconstructed with a single-incision, arthroscopic assisted techniques. Prophylactic antibiotic was given prior to the skin incision. The portals used for arthroscopy included the anteromedial portal and anterolateral portal. We used to do diagnostic arthroscopy prior to harvesting of the graft and any meniscal pathology will be addressed. The bone-patellar tendon-bone autograft was harvested via a longitudinal incision (usually 4-5 cm in length) over the patellar tendon. The graft was prepared into a bone-patellar tendon-bone construct with the leading suture on the patellar side. The notch was prepared using a curette and motorized shaver until the over the-top position and femoral ACL footprint were clearly demonstrated. The tibial stump was cleaned leaving a short amount of stump for reference and covering the graft. The tibial guide pin was inserted to the posterior half of the remnant using the Acufex-elbow-tipped tibial guide and tibial tunnel reamed according to the size of the graft. With the knee flexed at 90 degrees, a guide pin was passed through the tibial tunnel to the femoral tunnel position. The femoral tunnel was reamed according to the size of the graft. Using a suture passing pin, the graft was passed through the tibial tunnel into the femoral tunnel and the suture passing pin passing out distal to the anterolateral skin of the thigh. The fixation method for patellar tendon graft was using cannulated interference screws usually 7 x 25mm, 8 x 25mm and rarely 9 × 25mm. The femoral site was fixed at 120 degrees knee flexion with the screw guide pin passed through the tibial tunnel. After femoral fixation, tension was applied to the tibial bone block suture and the knee passed through several cycles of flexion-extension to pretension the graft. The tibial site was fixed at 20 degrees knee flexion. The interference screw fixation method over the femoral tunnel is called as orifice fixation. All over the world this method is still suggested to be gold standard. The point is raised that the screw goes away from the graft but it is a positive point because the interference screw holds the graft at the orifice by its head and then goes away from the graft to avoid the damage to the graft and interface in between graft and bone is kept free.77 After the procedure, an intra-articular vacuum drain was placed into the joint. The drain was removed at 48 hours postoperatively. The knee was placed in a compressive dressing and long knee brace locked in full extension.

Results

1. In GROUP I(BTB GROUP) majority 60% of the patients were in the age group 21 to 40 years and in GROUP II(Semitendonosus Group) majority 70% were in the age group 21 to 40 years.
2. It was seen that in both groups majority left side was more affected.
3. In both the groups the majority of the respondents were males.

4. In group I majority 65% respondents were having twisting injury, and 35% had hyperextension injury; Among group II majority 55% respondents were having hyperextension injury and 45% had twisting injury.

5. In Group I majority 65% had motor vehicle injury and 35% had sports injury; Among group II majority 60% had motor vehicle and 40% had sports injury.

6. In Group I all were positive for anterior drawer test , 19 for lachman test, 11 were positive for pivot shift test, 10 were positive for MC murrays test and grinding test;Among group II 19 were positive for anterior drawer test, 20 for lachman test, 13 were positive for pivot shift test, 7 were positive for grinding test and 5 were positive for MC murrays test.

7. Among group I 55% had ACL with meniscal tear and 45% had ACL tear;Among group II 75% had isolated ACL tear, 25% had ACL and meniscal tear.

8. Among group I in 55% both ACL reconstruction and Partial Menisectomy and in 45% only ACL reconstruction was done;Among Group II in 75% ACL reconstruction, and in 25% both ACL reconstruction and partial menisectomy was done.

9. IKDC at 6weeks,among group I 75% were<60 and 25% had >60; Among group II 70% were >60 and 30% were <60.

10. IKDC at 3 months, among group I 35% were<60 and 65% had >60; Among group II 25% were >60 and 75% were <60.

11. IKDC at 6 months, among group I 10% were<60 and 90% had >60;Among group II 95% were >60 and 5% were <60.

12. Range of motion at 6 weeks, among group I majority 55% had decreased range upto 30 degree, 25% had upto 40 degree and 20% had upto 20 degree; Among group II majority 60% had decreased range upto 30 degree, 25% had upto 40 degree and 15% had upto 20 degree.

13. Range of motion at 3 months, among group I majority 35% each had decreased range upto 10 degree and normal respectively, 25% had upto 20 degree and 5% had upto 30 degree, Among group II majority 35% had decreased range upto 10 degree, 30% had normal range, 20% had upto 20 degree and 15% had upto 30 degree.

14. Range of motion at 6 months,among both groups majority 85% normal range, 10% had 20 degree and 5% had upto 10 degree.

15. Quadriceps power, among group I- 20 patients had decreased power at 6 weeks, 20 had decreased power at 3 months and 3 had decreased power at 6months; Among group II- 20 patients had decreased power at 6 weeks, 19 at 3 months and 2 had decreased power at 6months.

16. Complications in group I- 2 had anterior knee pain, 2 had infection and 1 had extensor lag;Among group II- 1 had extensor lag, 2 had infection and 1 had laxity.

17. The mean p values of IKDC at 6weeks, 3 months and 6 months were 0.6, 0.57 and 0.78 respectively. As all the values are more than 0.05 which shows no statistical significant difference. According to this it was seen that there was no significant difference between the IKDC score results among group I and group II.

Discussion

Before 1970, the ACL reconstruction was perfomed by open methods with many different surgeries. But in 1976, professor Erikkson76 perfomed mini arthrotomy and fixed ACL with BTB graft. First arthroscopically assisted ACL reconstruction was performed in 1980 by Dave Dandy48 Cambridge, United Kingdom In 1974 Kennedy et al compared the long term results of 19 acute tears of the anterior cruciate ligament treated surgically and 31 acute tears not subjected to surgery. A follow up study after seven years showed that the untreated group had deteriorated far more significantly as compared to the treated group, though the short term follow up at 44 months had shown significant differences between the two groups. Therefore, he recommended repair of all acute anterior cruciate ligament tears to prevent long term sequelae. The goal of treatment is to return the injured patient to the desired level of function. After successfully performing the arthroscopic assisted ACL reconstruction with BTB graft the newer methods were also trying to emerge as a better option as change is the rule of life.The semi tendonosis or semi tendonosis with gracilis i.e. hamstring tendon graft was chosen as an option. BTB tendon so far was giving satisfactory results with static stability but having some problems with donor site morbidity and anterior knee pain. But both of these problems disappear within 2-3 years80 The newer methods of hamstring was having good cosmesis but inferior static strength and static stability79. Both the methods though having some positive and some negative points were again giving satisfactory results. The newer method of hamstring was easier to perform and cosmetically more acceptable so in many parts of world became popular .The failure rate of this popular method were more as compared to BTB method and the surgeon started investigating and comparing these two methods. Thousands of research paper were published all over the globe and the agonist and anatagonist opinion started coming up. Still the conscious of research was firm and persistent about the usefulness of both of the methods. Patients have accepted both the methods. The essence of research was pointing towards positive and negative points of both the procedures highlighting that BTB is a static stabilizer and gives more rotational stability. The system of aperture fixation can be easily applied to BTB graft78. BTB graft goes for bone to bone healing which is proved beyond doubt and gives excellent physiological fixation86. On the other hand BTB creates some donor site morbidity resulting in

anterior knee pain and hypoaesthesia.78,79 The research points out that hamstring is a more cosmetic alternative reflecting almost similar post operative success85. The hamstring is having a inferior type of tendon to bone healing resulting in fibrous healing and sometimes creating problem of tunnel widening and loosening of graft.79,82-84 The meta anylasis of Scandavian registry was more in favour of BTB and claimed more failure rates in hamstring due to merceline tape fixation or endobutton 5. Other meta analysis (Yunes et al) claimed 75% patients with BTB and 64% patients with hamstring returned to pre injury activity giving more credit to BTB.82 The world literature accepts the different procedures being performed for different types of grafts The selection of procedure is not the only important aspect but the perfection, surgical skill, the experience of surgeon for doing that procedure are equally important, the post operative protocol,physiotherapy has got equal importance. The selection of procedure also depends on demand of patient, if the patient is a non athelete having low profile sedentary activity and a women preferring cosmesis, the choice of graft can be hamstring. On the other hand an athelete with high profile activity level needing a strong and stable knee or a manual labourer, one has to consider the BTB.82 But the cosmesis and stability always does not go hand in hand. Real knee arthroscopic surgeon should master both the techniques and keep the ability to offer what the patient demands Having all this understood, we are aware of importance of post operative management of pain and swelling, protection of healing graft, restoration of full range of motion and neuromuscular proprioceptive control81, gradual and progressive return to pre injury activities have a vital role in the management of ACL replacement done by whichever method, the surgeon and the patient approves.

Conclusion

- Majority of study subjects were males i.e., 13out of 20 in bone tendon bone group and19 out of 20 in semitendinosusgroup.
- Mean age for bone tendon bone group (GROUP 1) was 33.65 years and for semitendinosus group(GROUP 2) was 25.75 yrs.
- 9 out of 20 in bone tendon bone group had isolated acl injury;15 out of 20 in semitendinosus had isolated acl injury.
- Most common mechanism of injury was Road Traffic Accident (13 in gp 1 and 12 in gp 2) and sports activity (7 in gp1 and 8 in gp 2)
- Bone tendon bone graft goes for bone to bone healing which is proved beyond doubt and given excellent physiological fixation.
- Semitendinosus graft is a more cosmetic alternative reflecting almost similarpost operative success.
- There is no difference in functional outcome of bone tendon bone and semitendinosus method.

References

1. Henry E. Bourke, Lucy J.Salmon, Alison Waller, Victoria Patterson and Leo A. Pinczewski. J; Pinczewski LA Arthroscopy 29 (1) 74-82 2013; Endoscopic Anterior CruciateLigament ; American Journal of Sports Medicine 2006; 34(5):721-32
2. LAPinczewski, J Lyman, LJ Salmon, VJ Russell, J Roe, J Linklater arthroscopic reconstruction of the anterior cruciate ligament A comparison of patellar tendon, Patellar versus hamstring tendons in anterior cruciate gament ;2007;413.
3. Laoruengthana A, Pattayakorn S, Chotanaputhi T,Clinical comparison between six-strand hamstring tendon and patellar tendon autograft in arthroscopic anterior cruciate ligament reconstruction: a prospective, randomized clinical trial. et al.Am J Sports Med 2009 ; 37: 1618 – 26 .38
4. COL (Ret) Dean C. Taylor, MD et allPatellar Tendon Versus Hamstring Tendon Autografts for Anterior Cruciate Ligament Reconstruction.A Randomized Controlled Trial Using Similar Femoral and Tibial Fixation Methods.58 Am J Sports Med. 2009 Oct;37(10):1946- 57.
5. Vairo GL, Mc Brier NM, Miller SJ, Buckley WE. Premature Anatomic double-bundle anterior cruciate ligament reconstruction. Arthroscopy. 2010; 19(1):86-97.
6. Oiestad BE1, Holm I, Aune AK, Gunderson R, Myklebust G, Engebretsen L, Fosdahl MA, Risberg MAKnee function and prevalence of knee osteoarthritis after anterior cruciate ligament reconstruction: a prospective study with 10 to 15 years of follow-up Am J Sports Med. 2010 Nov;38(11):2201-10
7. Heijne A1, Werner S.A 2-year follow-up of rehabilitation after ACL reconstruction using patellar tendon or hamstring tendon grafts: a prospective randomised outcome study. Knee Surg Sports Traumatol Arthrosc.2010 Jun;18(6):805-13.
8. Barenius B1, Nordlander M, Ponzer S, Tidermark J, Eriksson K.Quality of life and clinical outcome after anterior cruciate ligament reconstruction using patellar tendon graft or quadrupled semitendinosus graft: an 8-year follow-up of a randomized controlled trial;Am J Sports Med. 2010 Aug;38(8):1533-41.
9. Li, ShuZhen; Su, Wei; Zhao, Jinmin; Xu, Yinglong; Bo, Zhandong; et al. A meta-analysis of hamstring autografts versus bone-patellar tendon-bone autografts for reconstruction of the anterior cruciate ligament.The Knee Oct 2011; 287-93.
10. Shelbourne KD, Klootwyk TE, Decarlo MS.Update on accelerated rehabilitation after anterior cruciate ligament reconstruction.J Orthop Sports Phys Ther. 1992;15(6):303-8.
11. Irrgang JJ1, HoH,Harner CD, Fu FHUse of the International Knee Documentation Committee guidelines to assess outcome following anterior cruciate ligament reconstruction..;Knee Surg Sports Traumatol Arthrosc 1998;6(2):107-14

12. Aglietti P, Buzzi R, Zaccherotti G, DeBiase P. Patellar tendon versus doubled semitendinosus and gracillis tendons for anterior cruciate ligament reconstruction. Am J Sports Med 1994; 22: 211-8.

13. Snook GA A: short history of ACL and the treatment of tears : clinorthop ;1983;172: 11-13.

14. Robert H Miller : Knee injuries : in Campbell vol 2, 9th edition.

15. Collen M. Fay, MD. Complication associated with use of Anterior Cruciate Ligament Fixation Devices. The American Journal of Orthopedics – June 2011;40(6):305-10

16. Abe, S M Kurosaka, et al (1993). "Light and electron microscopic study of remodeling and maturation process in autogenous graft for anterior cruciate ligament reconstruction." Arthroscopy 9(4);1993; 394: 405.

17. Eriksson E; Reconstruction of the anterior cruciate ligament, Orthop Clin North Am 7;1976;167.

18. P.G. Kulkarni, Utkal Dudhwala. Arthroscopic Anterior Cruciate Ligament Reconstruction Using Bone Patellar Tendon Bone Graft; Journal of Trauma and orthopaedic surgery; Jan -March 2016;vol11;issue 1;page21-25

19. Michael Wagner ;Max j kabb;Jessica shallock;Norbert p.haas;andreas weiler. Hamstring Tendon Versus Patellar Tendon Anterior Cruciate Ligament Reconstruction Using Biodegradable Interference Fit Fixation. Am .J. Sport med, 2005;vol 33,1327-1336.

20.PaoloaGlietti,FrancescoGiron,RobertoBuzzi,FlavioBiddau,Francesco Sasso. Anterior cruciate ligament reconstruction:bone patellar tendon bone compared with double semitendinosus and gracilis tendon grafts.A prospective,randomized clinical trial J Bone Joint Surg Am 2004;86:2143-2155

21. Boonriong T, Kietsiriroje N. Arthroscopically Assisted Anterior Cruciate Ligament Reconstruction; Comparison of bone –patellar-tendon-bone versus hamstring tendon autograft . J Med Asso Thai 2004;87(9) :1100-7

22. Baur C., Mathieu N., Delamorclaz S., Hilfiker R., Blatter S., Siegrist O., Fournier S. Anterior cruciate ligament reconstruction: Hamstring Tendon autograft versus BonePatellar Tendon Bone autograft: what about muscular and functional capacities?.Schweizerische Zeitschrift für Sportmedizin und Sporttraumatologie 63 (2);2015; 18-22.

23. Alberto Gobbi, sanjeev Mahajan, M.S., Milco Zanazzo, and Benjamin Tuy, Patellar Tendon Versus Quadrupled Bone–Semitendinosus Anterior Cruciate Ligament Reconstruction: A Prospective Clinical Investigation in Athletes. Arthroscopy: The Journal of Arthroscopic and Related Surgery, Vol 19, No 6 (July-August), 2003: pp 592-601

24. Jakub Kautzner & Petr Kos & Martin Hanus & Tomas Trc &Vojtech Havlas A comparison of ACL reconstruction using patellar tendon versus hamstring autograft in female patients: a prospective randomised study. International Orthopaedics. January 2015 , Volume 39, Issue 1, pp 125–130

25. Navin Kumar Karn, Ranjiv Kumar Jha, Nishit Ranjan. Anterior Cruciate Ligament Reconstruction using Bone Patellar Tendon Bone autograft in ACL deficient Knee. Journal of College of Medical Sciences-Nepal, Vol-11, No 3, Jul-Sept 2015;12-15

26. Dr. Nikhil Joseph Martin, Dr. Shishir.S.M, Dr. Kanagasabai.R, Dr. Syed Najimudeen, Dr. James J Gnanadoss Quadruple hamstring tendon graft versus Bone-Patellar-Tendon-Graft for arthroscopic Anterior Cruciate Ligament reconstruction-comparison study with follow up of 2 years. IOSR Journal of Dental and Medical Sciences (IOSR-JDMS) Volume 13, Issue 11 Ver. IV (Nov. 2014), PP 06-13

27. Chouliaras V, Ristanis S, Moraiti C, Stergiou N, Georgoulis AD. Effectiveness of reconstruction of the anterior cruciate ligament with quadrupled hamstrings and bone-patellar tendon-bone autografts: an in vivo study comparing tibial internal-external rotation;9 Am J Sports Med. 2007 Feb;35(2):189-96.

Conflict of Interest: NIL
Source of Support: NIL

How to Cite this Article

Kulkarni PG, Bhagat S, Doshi R, Patel K. Comparative Study of Arthroscopic Anterior Cruciate ligament reconstruction by Bone Tendon Bone Method and Semitendinosus Method. Journal of Trauma and Orthopaedic Surgery Jan-March 2018;13(1):31-36.