Original Article

Journal of Trauma & Orthopaedic Surgery 2018; Jan- March; 13(1):21-26

Titanium elastic nailing in femoral diaphyseal fractures in children of 3-12 years age

Shishir Murugharaj Suranigi[1], Lingaraj[1], Shuaib Ahmed[1], Sundara Pandian Ravi[1], Dharunraj Venkatasubbu[1], Syed Najimudeen[1]

Abstract

Background: *Paediatric femoral diaphyseal fractures are still managed conservatively by many surgeons. They are often associated with various complications. With the advent of Titanium elastic nail system(TENS), ample number of surgeons are now opting for surgical management of these fractures.*

Materials and Methods: *Thirty-three children (24 boys, 9 girls) aged 3-12 years with femoral diaphyseal fractures were stabilized with Titanium Elastic Nail System(TENS). Out of the 33 children, 13 of them had proximal third shaft fracture, 16 of them had sustained middle third fracture and rest 4 of them had sustained distal third fracture. Fractures were classified according to system of Winquist and Hansen as Grade-I (n = 22), Grade-II (n =09), Grade-III (n =2)and the results were evaluated using the Flynn's scoring criteria.*

Results: *The average age of patients was 6.45 years(range: 3-12 years). All 33 patients were available for evaluation with a mean follow-up duration of 34 months (range: 16-62 months). Radiological union was achieved in all cases with a mean time of 10 weeks (range: 8-15 weeks). According to Flynn's scoring criteria, 24 patients (72.7%) had excellent outcome and 9 patients (27.3%) had satisfactory results. No patient had poor result. Most common complication in our study was nail irritation at the entry site. No cases of delayed or non-union were seen.*

Conclusion: *TENS is a minimally invasive, relatively safe and easy to use device for the treatment of paediatric femoral shaft fractures with excellent functional and radiological outcome.*

Keywords: *paediatric, femoral diaphyseal fractures, titanium elastic nail system(TENS), Flynn's criteria.*

Introduction

Femoral shaft fractures are among the most common major paediatric injuries treated by orthopaedic surgeons world-wide [1]. Rapid healing and remodeling of deformities has prompted many surgeons to treat this fracture conservatively even till date. Conservative management of these fractures results in prolonged immobilization, angulation, shortening, mal-rotation of the involved limb [2]. Complications such as loss of reduction, non-compliance or intolerance to plaster for long and its associated psychosocial problems also needs to be considered. Plating of femoral shaft fractures in children has been done traditionally by many surgeons with variable results. Plating of femoral shaft factures is an invasive process, with extensive dissection of muscles and soft tissues which eventually drains the fracture haematoma. It also results in intra-operative blood loss, increased risk of hospitalization and delayed rehabilitation and recovery [3,4]. Intra-medullary interlocking nails are not an option in children do to narrow canal and open physis [5]. The aim of femoral shaft fixation in children is to attain early mobilization which in turn encourages restoration of the movements of the adjacent joints. Achieving early pre-injury status hastens psychological recovery for the patient. Prolonged immobility and associated complications has prompted the use of surgical techniques that permit early mobilization. Operative stabilization of femoral shaft fractures has gained popularity in the last few decades due to the problems such as failure to obtain or maintain an acceptable reduction of the fracture by conservative methods and poor patient compliance with plaster spica [6,7]. All these concerns have been addressed by Titanium Elastic Nailing System (TENS). Titanium Elastic Nailing System (TENS) was introduced for femoral fractures by Nancy group in 1979, has gained popularity in the last three decades. They are flexible nails that allow adequate bending and avoid the need to cross the physis during their insertion. TENS requires relatively smaller incisions for insertion and easy hardware removal which results in a better scar acceptance compared to the other traditional operative techniques such as plating. TENS procedure per-se causes minimal soft-tissue trauma, quicker recovery and shorter hospital stays. These are weight sharing implants, hence results in early mobilization or early functional activity which encourages faster healing of fracture, preservation of tone of the muscles, restoration of the adjacent joint movements, prevention of psycho-social complications and high patient satisfaction rate [8-14]. Titanium is

[1]Department of Orthopaedics, Pondicherry Institute of Medical Sciences, Pondicherry-605014,India.

Address for correspondence:
Dr. Shishir Murugharaj Suranigi,
Associate Professor, Department of Orthopaedics, Pondicherry Institute of Medical Sciences, Pondicherry-605014,India.
Email: shishir100@gmail.com

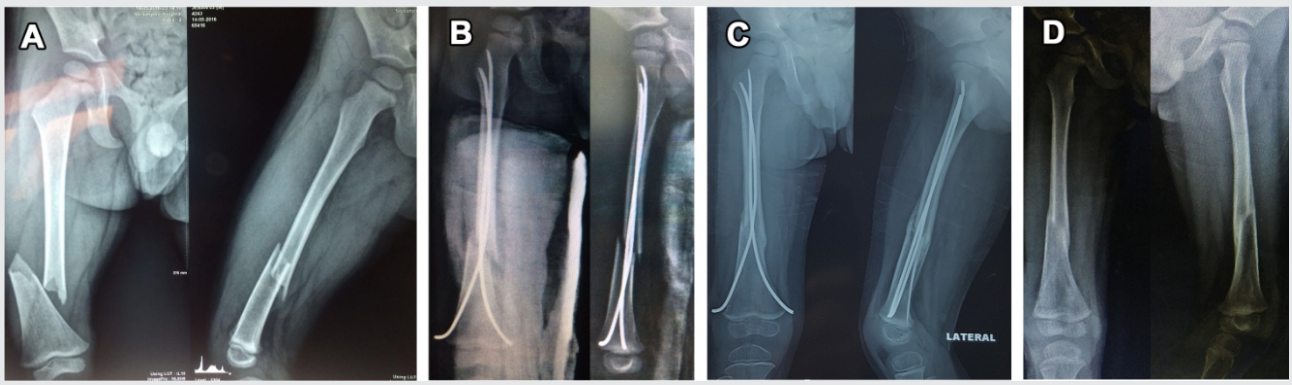

Figure 1: (A) Pre-operative radiographs of a 5 year old boy with right sided distal 1/3rd femoral shaft fracture. (B) Immediate post-operative radiographs showing good reduction of fracture with TENS in situ. Slab can also be noted on the radiograph. (C) Radiographs done at 8 weeks of follow-up showing excellent union at the fracture site. (D) Radiographs done at 10 months of follow-up of the same patient after implant exit showing excellent union.

Table 1: Clinical profile of patients and their fracture pattern.

Mean age at presentation	6.45 years (range: 3–12 years)
Sex	Boys (n=24)
	Girls (n=09)
Mode of injury	Road Traffic Accident (n=19)
	Fall (n=10)
	Sports related injury (n=04)
Fracture pattern	Transverse (n=10)
(n=33)	Oblique (n=12)
	Spiral (n=09)
	Comminuted(n=02)
Fracture location	Proximal (n=13)
(n=33)	Midshaft (n=16)
	Distal (n=04)
Side of fracture	Right (n=20)
	Left (n=13)
Winquist-Hansen Grade	I (n=22)
(n = 33)	II (n=09)
	III (n=02)

Table 2: Radiological assessment using Anthony et al grading for callus formation

Grade	Radiological Assessment
Grade 0	No identifiable fracture healing.
Grade 1	Primary bone healing with little or no periosteal new bone formation.
Grade 2	Periosteal new bone formation on two sides of the femur.
Grade 3	Periosteal new bone formation on three or four sides of the femur.

preferred over other metals or alloys because its excellent biocompatibility and elasticity limits the nail from becoming permanently deformed during insertion. This in turn promotes callus formation by limiting stress shielding. TENS achieves axial and rotatory stability through the so called 3 point fixation and resulting internal bracing [15].

Materials and Methods

This is a prospective study conducted between November 2010 and September 2017. After obtaining approval from our institutional board, 33 paediatric patients of either sex, aged 3-12 years having closed

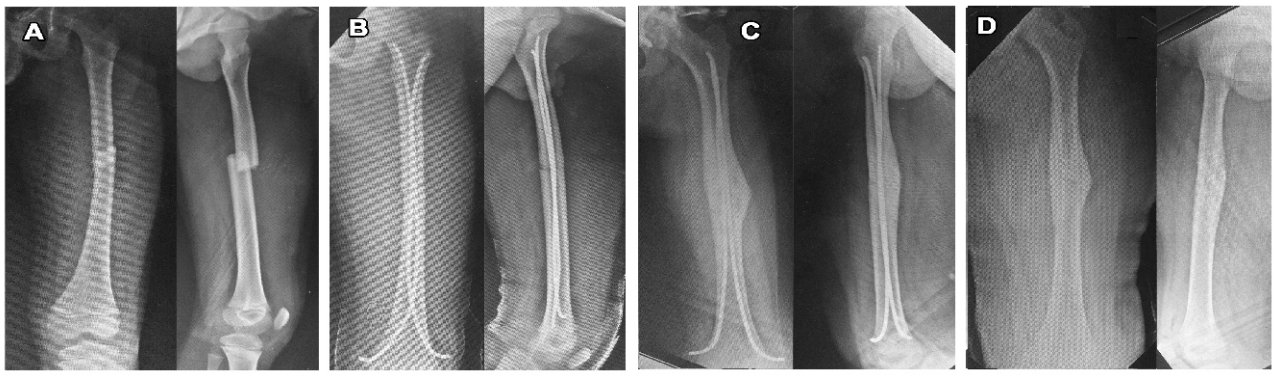

Figure 2: (A) Pre-operative radiographs of a 10 year old boy with left sided middle 1/3rd transverse femoral shaft fracture. (B) Immediate post-operative radiographs showing good reduction of fracture with TENS in situ. (C) Radiographs done at 12 weeks of follow-up showing excellent callus at the fracture site. (D) Radiographs done at 9 months of follow-up of the same patient after implant exit showing excellent union.

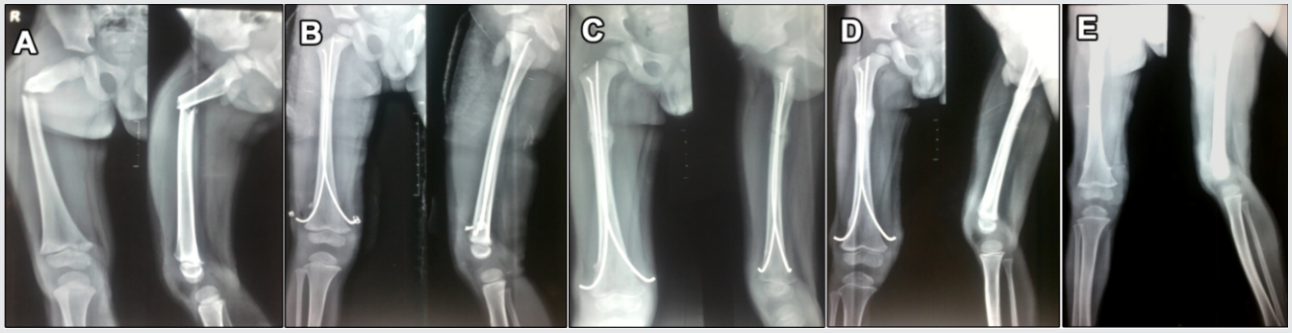

Figure 3: (A) Pre-operative radiographs of a 3 year old boy with right sided proximal 1/3rd femoral shaft fracture with significant rotation and flexion of the proximal fragment. (B) Immediate post-operative radiographs showing good reduction of fracture with TENS in situ. (C,D) Radiographs done at 3 weeks and 8 weeks of follow-up respectively, showing excellent callus at the fracture site. (E) Radiographs done at 10 months of follow-up of the same patient after implant exit showing excellent union and remodelling

femoral diaphyseal fractures were included. Informed consent was taken from their parents/ guardians and these patients were treated with TENS. Closed fractures were classified according to Winquist-Hansen. Pathological fractures, re-fracture, fractures associated with metabolic bone disease, children with neuromuscular diseases, poly-trauma and non-ambulatory children were excluded from this study. We did not use any control group in our study. The study consisted of 24 boys and 9 girls with an average age of 6.45 years (range: 3–12 years) at the time of injury. The most common mode of injury was road traffic accident (n=19, 57.6%) followed by fall from height (n=10,30.3%) and rest were due to sports related (n=4, 12.1%). Right sided (n=20,60.6%) involvement was more than left side (n=13,39.4%). Thirteen fractures (39.4%) were in the proximal 1/3rd, 16 (48.5%) were in the middle 1/3rd and 4(12.1%) were in the distal 1/3rd. The various fracture patterns in the study were, transverse (n =10), oblique (n=12), spiral (n=9) and comminuted (n=2). Fracture comminution was categorized according to system of Winquist and Hansen as Grade-I (n=22), Grade-II (n=09), Grade-III (n=2) [16] [Table 1]. The mean time from injury to surgery was 4.1 days. All the fractures were treated by a single team of doctors and uniformity in the surgical procedure was followed. All of them underwent two pre-bent Titanium Elastic Nails of identical diameter passed percutaneously under C-arm fluoroscopic guidance on the fracture table, one from medial and other from lateral aspect of the distal femur approximately one inch proximal to the physis. Pre-operative radiographic assessment of the medullary canal was done to determine the diameter of the nail to be used. We achieved closed reduction in all the cases. Proximal third shaft fractures were difficult to reduce due to rotated and flexed proximal fragment. Patients were started with knee mobilisation and non-weight bearing walking with the help of walker frame on the first post-operative day. Partial weight bearing was allowed at 3 weeks as tolerated with the help of walker/crutches and full weight bearing was started after radiological evidence of union as proposed by Anthony et al [Table 2] . Patients were followed up clinically and radiologically at monthly intervals for first three months, then at three monthly intervals till one year after surgery and once in 6 months thereafter. The final results were evaluated using the Flynn's scoring criteria [Table 3]. Nails were removed between nine months to 1 year after surgery when the fracture line was no longer visible radiologically. The aims and objectives of this study is to find out the outcome of TENS fixation and to compare the findings of this study with pre-existing literature.

Table 3: Flynn's scoring criteria and outcome.

Parameters	Excellent	Satisfactory	Poor
Leg length inequality	<1 cm	<2 cm	>2 cm
Mal-alignment	5 degrees	10 degrees	>10 degrees
Pain	None	None	Present
Complication	None	Minor and resolved	Major and/or lasting morbidity
Patient results (n=33)	24 (72.7%)	09 (27.3%)	0

Table 4: Results

Parameters	Results
Injury-hospital duration	7.44 days(range: 3-22 days)
Total Hospital stay	5.5 days (range: 3- 19 days)
Injury- surgery interval	2.33 days (range: 1-7 days)
Nail diameter used	2.5 mm to 4 mm
Type of reduction	All closed reduction
Duration of surgery	48.8 min (range: 30-100 min)
Entry site irritation	5 patients
Mean duration of follow-up	34 months (range: 16-62 months)
Time for union	10 weeks (range: 8-15 weeks)
Full weight bearing	13.4 weeks (range: 8-16 weeks)
Limb Length Discrepancy	4 cases
Malunion	2 patients (1 varus,1 valgus)
Non-union	Nil

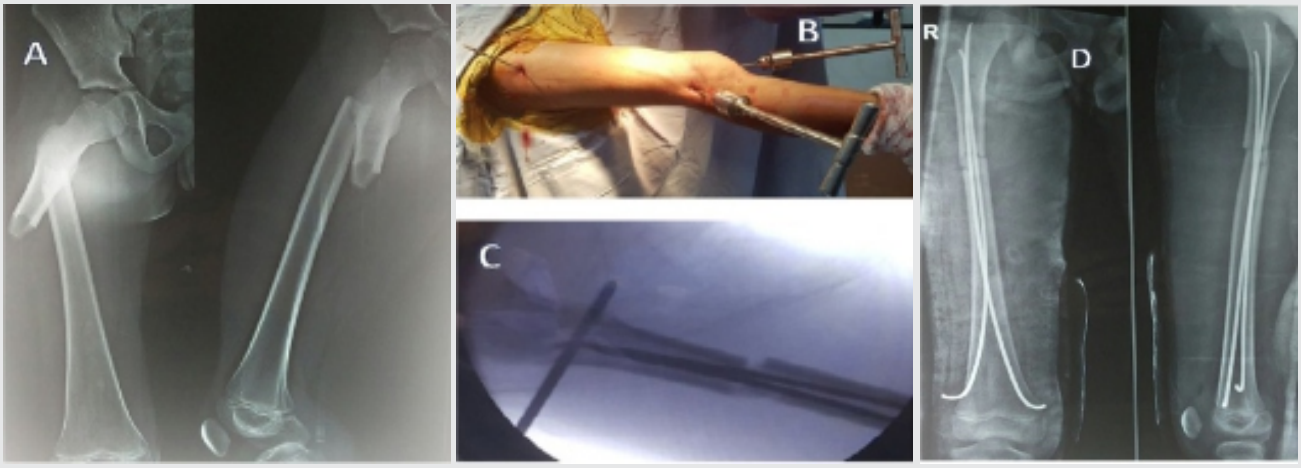

Figure 4: (A) Pre-operative radiographs of a 9 year old boy with right sided proximal 1/3rd femoral shaft fracture with significant rotation of the proximal fragment. (B) Intra-operative photograph of the Steinman pin inserted percutaneously at the proximal femur and both the TENS being advanced simultaneously across the fracture site. (C) Intra-operative C-arm image of the reduction being achieved using the Steinmann pin. (D)Immediate post-operative radiographs showing good reduction of fracture with TENS in situ.

Results

The median duration of surgery was 48.8 min (30-100 min). Mean hospital stay was 5.5 days (range: 3- 19 days). One patient had facial fractures requiring fixation after the swelling reduced. Hence the extended stay of 19 days. The mean duration of follow-up was 34 months (range: 16-62 months). Mean interval between injury and definitive surgery was 2.33 days (range: 1-7 days). Minimum TENS nail size used was 2.5 mm while maximum TENS nail size used was 4 mm. None of the fractures needed open reduction. Post-operatively, one patient aged 12 years with middle third fracture and communition was initially put on above knee slab for 3 weeks. Hip spica was not used in any of our patients [Figure 1]. Bridging callus was observed on follow-up radiographs at an average of 4.2 weeks. All fractures in this series united with grade 3 callus formation in a mean duration of 10 weeks (range: 8-15 weeks). Seventeen patients found to achieve union at 8 weeks, 12 patients at 12 weeks and 4 patients at 16 weeks duration [Figure 2]. The average time of full weight bearing was 13.4 weeks (range: 8-16 weeks). Thirty-one patients achieved full range of knee and hip motion while two cases had terminal restriction of knee flexion (20 and 30 degrees). These patients were admitted for rehabilitation and achieved full range subsequently.According to Flynn's scoring criteria, 24 patients (72.7%) had excellent outcome, 9 patients(27.3%) had satisfactory results. There were no poor results in our study. Two patients of Winquist and Hansen Grade-I, 5 patients of Grade II and two patients of grade III showed satisfactory results. Most common complication in our study was nail irritation at entry site. Five patients complained of entry site irritation. One of them needed shortening of TENS nail in order to reduce bursitis. Another patient developed ulceration due to entry site irritation of the nail. The ulcer was debrided and nail was shortened. Three patients had superficial skin infection at the nail entry site which required debridement and oral antibiotics. They subsequently subsided. We noted 4 cases of limb length discrepancy, all had lengthening. Out of four cases only one showed lengthening of 2.0 cm and rest three were of less than 1 cm. Two patients had mal-union, one varus angulation of 5 degrees and other with 15 degrees of valgus angulation. No intervention was done in both these cases. The thigh-foot angle was used to measure rotational alignment which was symmetrical in all our cases. No cases of delayed union or non-union were seen [Table 4]. There were no cases of implant failure noted in our series. All patients in our series underwent nail removal at a mean duration of 9.8 months (range: 9 to 12 months). We did not face any complications while nail removal and no re-fractures were observed after nail removal until last follow-up [Figure 3].

Discussion

Conservative treatment was the preferred method for the treatment of diaphyseal fractures in children and young adolescents until recently. Many surgeons even now prefer to treat femoral shaft fractures conservatively with hip spica application [1,3]. We prefer to use hip spica in children less than 3 years of age. However, surgical management of femur fractures in children has reduced the ill-effects of prolonged immobilization, loss of school days and resulted in faster healing of fracture. Hence, operative management has been gaining popularity for the last three decades [4,5,8,9]. Plating of these fractures results in large exposure, delayed mobilisation, evacuation of fracture haematoma, increases the risks of delayed union and infection [6]. The external fixator is usually preferred in open fractures as a temporary fixation till the soft-tissue condition improves. Use of fixator for primary fracture fixation results in good stability and early mobilization of hip and knee joint, but is associated with the risk of

pin tract infections and it takes a longer time for weight bearing [17]. Intra-medullary interlocking nails are not preferred in young and growing children [18]. Reports of avascular necrosis of femoral head and coxa valga deformity occurring due to the damage to the trochanteric physis have been reported with interlocking nailing in skeletally immature patients [5]. Children above the age of 12 years are managed by interlocking nails in our institute. This is in accordance with many authors who have reported the use of interlocking nails as early as 12 years, avoiding the pyriformis fossa as entry site, with good results [3,4,17,18]. Intra-operatively, we faced difficulty in reducing proximal 1/3rd femoral fractures. In 9 out of the total 16 cases of proximal 1/3rd fractures, we used a Steinmann/schanz pin in the proximal fracture fragment as a joy stick to reduce the fracture and counter the forces of flexion, external rotation and abduction. Once the TENS were advanced simultaneously from the medial and lateral side of the distal thigh and across the fracture site, the Steinman/schanz pin was withdrawn and held unicortical till the complete passage of TENS into the neck and trochanter respectively. Reduction was confirmed under image intensifier [Figure 4]. Cosmetically, plating results in a large scar formation as compared to TENS application. Removal of these implants, whether plate or nail is imperative as it may hinder the growth of the bone, especially the width of the bone. TENS removal is much easier as compared to plates as it requires stab incisions only. It is important to remove the TENS after fracture union otherwise these nails get incorporated in the femur as the bone grows and their removal becomes very difficult [19,20]. Hence, we removed TENS in all our patients at a mean duration of 9.8 months from surgery. Nectoux et al advocated the use of end caps for easy removal of the nails after bone healing, thereby preventing the formation of ossification over the tips of the nails. This also appeared to protect the skin next to the nail tip and resulted in lesser skin irritation [21]. TENS is superior to the other surgical methods particularly in this age group because it avoids open physis, allows early mobilization and maintains alignment. It also allows micro-motion at the fracture site resulting in faster external bridging callus formation as it provides relative stability at the fracture site. The haematoma and the periosteal blood supply is not disturbed and being a minimally invasive procedure, the risk of infection is grossly reduced [10-12]. Buechsenschuetzet al, concluded that titanium nails were superior compared to hip spica in terms of union, scar acceptance and overall patient satisfaction rates [22]. In a series of 123 femoral shaft fractures treated with elastic stable intramedullary nail, Ligier et al documented union in all of their fractures. They further stated that, Ender Nail was not elastic and flexible enough for paediatric fractures as the TENS. The most common complication in their study was entry site irritation [23]. In our series also entry site was detected in 5 patients. Fracture geometry and the location plays an important role in selection of surgical procedure. Lascombes et al stated that TENS could be used in all femoral diaphyseal fractures of children, six years of age till physis closure [24]. Narayanan et al and Flynn et al concluded that transverse, short oblique, short spiral fractures with minimum comminution in the 5-12 years age group were the best indications for TENS [25,6]. Literature suggests that TENS does not provide adequate stability in comminuted, long oblique or spiral fractures. This is because angulation occurs at the fracture site and hence, post-operative immobilisation in the form of cast/slab/brace is required. There was one 5 year old boy who sustained distal 1/3rd spiral shaft femur fracture which was immobilised by above knee slab for 3 weeks as we felt that the fracture was unstable and the principle of TENS did not apply in his case [Figure 1B]. Mobilisation of the knee was started after 3 weeks. He attained full range of motion in 6 weeks and fracture united in 8 weeks without any significant malunion. Narayanan et al in their first 5-year experience of TENS with 78 children with 79 femoral fractures reported complications such as pain/irritation at the insertion site (n=41), radiographic malunion (n=8), refracture (n=2), transient neurologic deficit (n=2) and superficial wound infection (n=2). Most common cause of re-operation was due to mismatched diameters of the nails and comminution of more than 25%. Most complication was again entry site pain due to long or pre-bent nails [25]. Leaving untrimmed long end of the nail (>2 cm) was significantly associated with entry site irritation and limitation of knee movements in our cases also.

Conclusion

TENS has evolved as a first line of management in paediatric femoral fractures. It is a technically simple, minimally invasive and a reliable procedure with minimal complications. It provides relative fracture stability, reduces hospital stay, helps in early mobilisation and early return to function.

References

1. Hinton RY, Lincoln A, Crockett MM, Sponseller P, Smith G. Fractures of the femoral shaft in children. Incidence, mechanisms, and socio demographic risk factors. J Bone Joint Surg Am. 1999; 81(4):500–509.
2. Sanders JO, Browne RH, Mooney JF. Treatment of femoral fractures in children by pediatric orthopaedists: results of a 1998 survey. J Pediatr Orthop. 2001; 21:436–441
3. Flynn JM, Hresko T, Reynolds RA, et al. Titanium elastic nails for Pediatric femur fractures: A multicenter study of early results with analysis of complications. J Pediatr Orthop. 2001; 21(1): 4-8.
4. May C, Yen YM, Nasreddine AY, Hedequist D, Hresko MT, Heyworth BE. Complications of plate fixation of femoral shaft fractures in children and adolescents. J Child Orthop. 2013;7(3):235–243.
5. Buford D, Christensen K, Weather P. Intramedullary nailing of femoral fractures in adolescents. Clin Orthop Relat Res. 1998;350(5):85-9.
6. Flynn JM, Skaggs D, Sponseller PD, Ganley TJ, Kay RM, Leitch K. The operative management of pediatric fractures of the lower extremity. J Bone Joint Surg Am. 2002; 84(12) :2288–2300.
7. Metaizeau JP. Stable elastic intramedullary nailing for fractures of the femur in children. J Bone Joint Surg Br.2004; 86(7):954–957.
8. Khazzam M, Tassone C, Liu XC, Lyon R, Freeto B, Schwab J, Thometz. J Use of flexible intramedullary nail fixation in treating femur fractures in children. Am J Orthop.2009;38(3):49–55.
9. Saikia KC, Bhuyan SK, Bhattacharya TD, Saikia SP. Titanium elastic nailing in femoral diaphyseal fractures of children in 6–16 years of age. Ind J Orthop.2007; 41(4):381–385.
10. Singh R, Sharma SC, Magu NK, Singla A. Titanium elastic nailing in pediatric femoral diaphyseal fractures. Ind J Orthop.2006; 40(1):29–34.
11. Bopst L, Reinberg O, Lutz N. Femur fracture in preschool children:experience with flexible intramedullary nailing in 72 children. J Pediatr Orthop. 2007;27(3):299–303.
12. Anastasopoulos J, Petratos D, Konstantoulakis C, Plakogiannis C, Matsinos G. Flexible intramedullary nailing in paediatric femoral shaft fractures. Injury. 2010; 41(6) : 578-582.
13. Houshian S, Gøthgen CB, Pedersen NW, Harving S. Femoral shaft fractures in children: elastic stable intramedullary nailing in 31 cases. Acta Orthop Scand. 2004; 75(3):249–251.
14. Sanzarello I, Calamoneri E, D'Andrea L, Rosa MA. Algorithm for the management of femoral shaft fractures in children. Musculoskelet Surg. 2014; 98(1): 53-60.
15. Mahar AT, Lee SS, Lalonde FD, Impelluso T, Newton PO. Biomechanical comparison of stainless steel and titanium nails for fixation of simulated femoral fractures. J Pediatr Orthop. 2004; 24(6):638–641.
16. Winquist RA, Hansen RT, Clawson DK. Closed intramedullary nailing of femoral fractures. A report of five hundred and twenty cases. J Bone Joint Surg Am.1984; 66(4):529-539.
17. Slongo TF. Complications and failures of the ESIN technique. Injury. 2005; 36(1):S-A78–S-A85.
18. Hosalkar HS, Pandya NK, Cho RH, Glaser DA, Moor MA, Herman MJ. Intramedullary Nailing of Pediatric Femoral Shaft Fracture. J Am Acad Orthop Surg. 2011. 19(8): 472-81.
19. Moroz LA, Launay F, Kocher MS, Newton PO, Frick SL, Sponseller PD, et al. Titanium elastic nailing of fractures of the femur in children. Predictors of complications and poor outcome. J Bone Joint Surg Br.2006; 88(10):1361–1366.
20. Wall EJ, Jain V, Vora V, Mehlman CT, Crawford AH. Complications of titanium and stainlesssteel elastic nail fixation of pediatric femoral fractures. J Bone Joint Surg Am.2009; 91(8):2040-2041.
21. Nectoux E, Giacomelli MC, Karger C, Gicquel P, Clavert JM. Use of end caps in elastic stable intramedullary nailing of femoral and tibial unstable fractures in children: preliminary results in 11 fractures. J Child Orthop.2008; 2(4):309–314.
22. Buechsenschuetz KE, Mehlman CT, Shaw KJ, Crawford AH, Immerman EB. Femoral shaft fracture in children: traction and casting versus elastic stable intramedullary nailing. J Trauma. 2002;53(5):914-921.
23. Ligier JN, Metaizeau JP, Prevot J, Lascombes P. Elastic stable intramedullary nailing of femoral shaft fractures in children. J Bone Joint Surg Br. 1988;70(1):74–7.
24. Lascombes P, Haumont T, Journeau P. Use and abuse of flexible intramedullary nailing in children and adolescents. J Pediatr Orthop. 2006;26(6) :827–34.
25. Narayanan UG, Hyman JE, Wainwright AM, Rang M, Alman BA. Complications of elastic stable intramedullary nail fixation of pediatric femoral fractures, and how to avoid them. J Pediatr Orthop. 2004;24(4):363-369.

Conflict of Interest: NIL
Source of Support: NIL

How to Cite this Article

Suranigi S M, Lingaraj, Ahmed S, Ravi S P, Venkatasubbu D, Najimudeen S.Titanium elastic nailing in femoral diaphyseal fractures in children of 3-12 years age. Journal of Trauma and Orthopaedic Surgery Jan-March 2018;13(1):21-26.