Original Article

Journal of Trauma & Orthopaedic Surgery 2016; July - Sep; 11(3):12-18

# Unstable Intertrochanteric fractures: Comparison of Proximal Femoral Nail Anti-rotation 2 and Short Proximal Femoral Nail

Sunil G. Kulkarni[1], Pradhyumn P. Rathi[1], Govind S. Kulkarni[1], Sagar P. Saxena[1], Priyanshu P. Dixit[1]

## Abstract

***Background:*** Intertrochanteric fractures are one of the most common fractures of the hip, seen in elderly population. The goal of treatment is to allow early mobilisation to prevent complications due to old age. Intramedullary nailing has recently become a popular method of stabilization. The aim of this study is to investigate and compare the radiological and clinical outcomes of PFNA-2 and Short PFN as intramedullary devices in the treatment of unstable intertrochanteric fractures, so as to help guide clinical decision-making.

**Materials & Methods:** 53 patients were treated in our hospital for intertrochantric fracture by cephalomedullary nailing using PFNA-2 and Short PFN. Radiological assessment of fracture reduction was performed using the fracture gap and the Gardens alignment index, device positioning was assessed using the Cleveland zones and the CalTAD (calcar referenced Tip-Apex Distance) measurement. Clinical outcome was documented as pain about the hip and thigh, walking ability Palmer and Parker Mobility score , patient satisfaction and modified Harris Hip score.

**Results:** No Significant differences are found between the groups in preoperative characteristics. Of the 53, 45 had fractures due to trivial trauma. Additional screw was required in 7 PFNA-2 and 21 Short PFN group patients. The mean CalTAD for the PFNA 2 group was 17.259 mm, while for the Short PFN group was 21.962 mm. Of the 14 malalignments of more than 5 degrees that were recorded on mean follow up of 15 months(12-24 months), 4 were in the PFNA2 group and 10 in the Short PFN group, with a prevalence of varus malalignment.

**Conclusions:** CalTAD and Cleveland Zones are important indices of tip position and predictors of screw/blade migration. PFNA 2 seems currently to be the optimal implant, especially in old, severely osteoporotic patients with unstable intertrochantric fractures. The choice of implant should be done pre-operatively by evaluating fracture pattern and geometry, bone quality and age.

**Key-words:** intertrochanteric fractures, intramedullary nails, Fracture Fixation

## Introduction

Intertrochanteric fractures are one of the most common fractures of the hip. They are mostly seen in elderly people with osteoporosis. Due to the aging population, by 2040 the incidence is estimated to be doubled. In India the figures may be much more [1]. The goal of treatment is anatomical fracture reduction and stable fixation to allow immediate mobilisation, reducing the incidence of complications due to old age, like pneumonia, urinary tract infection and cardiovascular events. Evans observed that the key to a stable reduction is the restoration of the posteromedial cortical continuity [2]. Unstable intertrochanteric fractures are those in which comminution of posteromedial buttress exceeds a simple lesser trochanteric fragment or those with subtrochanteric extension. There is comminution of greater trochanter and there is no contact between proximal and distal fragment because of displaced posteromedial fragment3. Similarly intertrochanteric fracture with reversed obliquity in which there is inherent tendency of medial displacement of distal fragment secondary to pull by adductor muscle are unstable fractures [4]. Another unstable fracture is described by Kyle, where intertrochanteric fracture is extended in to the fracture neck femur [5]. The results of unstable fractures are less reliable and have a high rate of failure (8%-25%) [3]. The importance of displaced lesser trochanter fragment, its size and displacement is a key to decide the instability of intertrochanteric fracture.

The sliding hip screw and plate fixation technique is considered the "gold standard" in the treatment of intertrochanteric fractures [6]. Unfortunately, it has reported a failure rate of 8-13 percent, which is associated with revision surgery, protracted in-hospital stay, increased risk of infections and decreased chance of autonomy and mobility [7]. Intramedullary nailing has recently become a popular method of stabilisation of unstable intertrochanteric fractures in adults [8].

The proposed advantages include a short incision, less operative time , minimal blood loss and rapid rehabilitation of the elderly patient [9]], which is essential to minimise the risk of medical complications. Several studies have shown the superiority of intramedullary

[1]Department of Orthopaedics, Post Graduate Institute of Swasthiyog Pratishthan Miraj, Maharashtra-416410 India.

**Address for correspondence:**
Dr. Dr.Pradhyumn P. Rathi
Department of Orthopaedics, Post Graduate Institute of Swasthiyog Pratishthan Miraj, Maharashtra-416410 India

Email- pradhyumnrathi@gmail.com

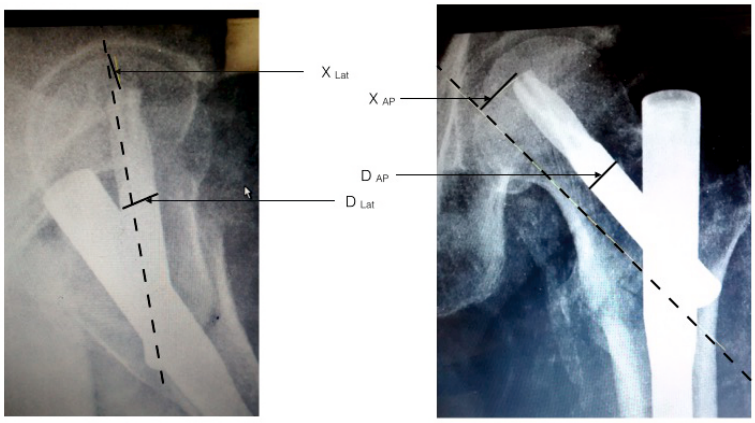


$$\text{CalTAD} = \left\{ X_{Lat} \times \frac{D_{true}}{D_{Lat}} \right\} + \left\{ X_{AP} \times \frac{D_{true}}{D_{AP}} \right\}$$

**Figure 1:** Calcar referenced Tip-Apex Distance calculated in radiographs in AP view and LAT view. Dtrue is known diameter of the helical blade (14 mm). X is tip-apex distance in AP and Lat Views ($X_{AP}$, $X_{Lat}$).


**Figure 2:** Proximal Migration of PFNA-2 helical blade.

nailing in this respect compared to other methods of fixation [10]. Optimal positioning of the nail devices is of paramount importance for a good outcome, reducing the risk of complications. Complications described with intramedullary devices include fracture propagation, difficulties with interlocking, jamming of the compression screw within the nail, and cut-out and cut-off of the lag screw [11].

PFNA system was developed by the AO/ASIF in 2004. The main design characteristic of the implant is the use of a single helical blade with a large surface area. Insertion of the blade compacts the cancellous bone. These characteristics provide optimal anchoring and stability when the implant is inserted into osteoporotic bone [12].

Short Proximal Femoral Nail was introduced in India by Gadegone WM, Salphale YS [13], who reviewed outcomes of 100 Asian patients undergoing short proximal femoral nailing for stable and unstable intertrochanteric fractures. They concluded, that short proximal femoral nail is a superior implant for stable and unstable intertrochanteric fractures in terms of operating time, surgical exposure, blood loss, and complications, especially for patients with relatively small femora.

Both PFNA-2 and Indian short PFN are widely used in India in the treatment of intertrochanteric fractures. The aim of this study is to investigate and compare the radiological and clinical outcomes of these intramedullary devices in the treatment of unstable intertrochanteric fractures, so as to help guide clinical decision-making.

## Material and Methods

Between May 2013 and May 2015, 53 consecutive patients were treated in our hospital for intertrochantric fracture. After Approval from the Ethics and Scientific Committee, patients were assigned in two groups for treatment with PFNA-2 (Proximal femoral nail anti-rotation-2, Synthes) or Indian Short PFN.

Inclusion criteria were patients with isolated, unstable, closed with Evans [2] type 2,3,4,5 intertrochantric fractures. Exclusion criteria were pathologic fracture due to other than osteoporosis, multiple trauma, and life expectancy of less than 3 months.

After taking a written informed consent, operations were performed by an expert surgeon. Operations were performed on traction table in supine position and closed reduction was performed with image intensifier guidance. Surgery was performed using standard protocol, as recommended by the manufacturer. We used a titanium cannulated 170 mm long by 10-12 mm diameter PFNA-2 nail has a proximal diameter of 16.5 mm with a lateral flattened surface and a medial-lateral angle of 5 degrees. The helical blade of 14 mm diameter was inserted in femoral neck without drilling. The Short PFN is a 180 mm long by 10-12 mm diameter cannulated stainless steel nail with a medial-lateral angle of 6 degrees and a longitudinal slot throughout to accelerate regeneration of endosteal bone. Two bolts were inserted into the neck of femur of 8 mm and 6.4 mm. Additional screws were inserted to provide stability. Stainless steel wire was used by applying the tension band principle for comminuted greater trochanter. Medullary canal was not reamed, and the nails were hammered. Both the nails were dynamically or statically locked distally. The caput-collum-diaphyseal(CCD) angle, of both the devices was 130 degrees. Both were inserted using percutaneous technique. In all the cases, ceftriaxone antibiotic was given pre-operatively and thromboprophylaxis with low molecular weight heparin was administered. Post-operative rehabilitation was started at the earliest.

The trauma to surgery duration, the length of operative

time, image intensifier time, duration of hospital stay and complications(intra-operative, post-operative and medical) were recorded. Post-operative radiographs were performed in Anterior-Posterior and Lateral views. Radiological assessment of fracture reduction was performed using the fracture gap and the Gardens alignment index, device positioning was assessed using the Cleveland zones [14] and the CalTAD [15] (calcar referenced Tip-Apex Distance) measurement as shown in Figure1. Malalignment was defined as varus-valgus of more than 5 degrees. Clinical and radiological assessment for device position, bone healing, secondary malalignment was performed at 3-6 month and at more than 1 year follow-up. Clinical outcome was documented as pain about the hip and thigh, walking ability Parker and Palmer Mobility score [16] , patient satisfaction and modified Harris Hip score [17].

For both the groups, data was represented as mean and standard deviation for continuous variables or, frequency and percentages for discreet variables. Statistical analysis of the differences was performed using the Student Paired t-test for continuous variables, and Chi-square test for discreet variables.

## Results

The preoperative characteristics of both the PFNA-2 and Short PFN groups are shown in the table1. No Significant differences are found between the groups regarding age, sex, side, Evans type of fracture. The mean follow up was 15 months (12-24 months). There were 27 patients in PFNA-2 group and 26 in Short PFN group. At the final follow-up 2 patients died from the PFNA-2 group. No patient was lost to follow-up.Out of the 53 patients 8 suffered trauma due to RTA and 45 had trivial trauma.

No significant difference was found in the trauma to surgery time , operative time as shown in table 2. However the image intensifier time for the PFNA-2 group was significantly lesser.

The mean duration of hospitalisation for the PFNA-2 group was 9.185 days(5-22 days) and for Short PFN group was 9 days(7-14 days), with resulting no significant difference. No intra-operative complications were noted.

Additional screw was required in 7 patients of PFNA-2 group and 21 patients of the Short PFN group to provide an adequately stable fixation. One patient each in both groups with Evans type 4 fracture with greater trochantric comminution was fixed with stainless steel wire using tension band principle. In the Short PFN group 1 patient required 2 additional screws to provide adequate stability.

Fracture reduction was assessed using the post-operative fracture gap and Garden alignment Index. The

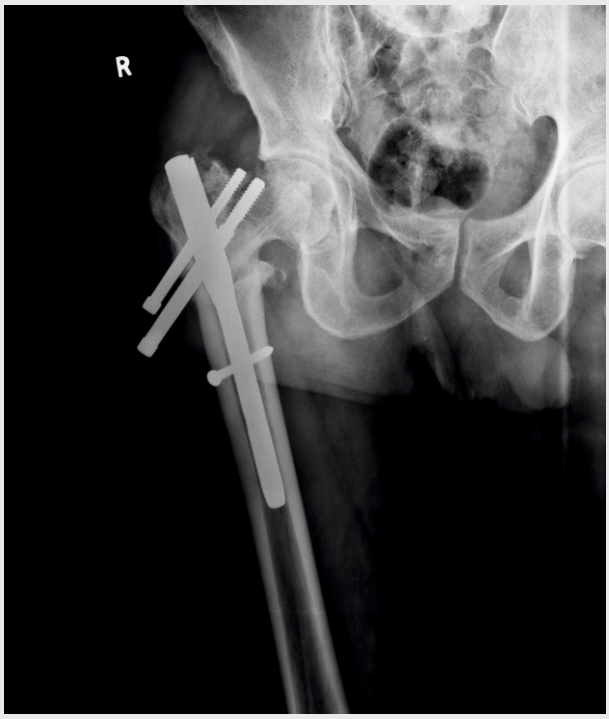


**Figure 3:** Showing cephalad cut-out in Short PFN.

mean postoperative fracture gap in the PFNA-2 group was 3.611 mm (0-18 mm) and in Short PFN group was 2.365 mm (0-10 mm). The mean Garden Alignment Index in the PFNA-2 group was 160.11 degrees (146-190 degrees) and in the Short PFN group was 155.61 degrees (130-178 degrees). The implant tip position was recorded according to the Cleveland zones and CalTAD. The tip of the helical blade of the PFNA-2 was within Cleveland zone 5 in 87.05 percent (23 patients) and the tip of the lag screw of the Short PFN was in zone 5 in 71.15 percent (19 patients). Statistical analysis between the two groups revealed no significant difference.

On average , the CalTAD for the PFNA-2 group was 17.259 mm (5-36 mm) for the spiral blade, while for the Short PFN group was 21.962 mm (10-36 mm). Statistical analysis between the two groups revealed a significant difference, with implant position being mare accurate in the PFNA-2 group. There was no statistically significant difference in the follow-up mean CalTAD measured at 3-6 months and at more than 12 months. However, the mean CalTAD in the Short PFN group decreased by 1.193 mm at the 12 month follow-up.

There were over-all 4 complications in the PFNA-2 group and 7 in the Short PFN group. Most of the complications are related to the blade, or lag screw migration.In the PFNA-2 group 2 patients had proximal migration (cut in)(Figure 2) and 2 had distal migration (back-out). In the Short PFN group there were 3 back-outs (Figure3), 1 screw cut-in and 1 Z-effect. In the Short PFN group 1 patient suffered implant failure (nail breakage) which was further replaced with a longer nail and 1 developed non-union which got re-operated with

Table 1: Comparison of Demographic characteristics of the two groups

| | | | | p value |
|---|---|---|---|---|
| sex | type | | Total | 0.922 |
| | PFNA-2 | Short PFN | | |
| Female | 9 | 9 | 18 | |
| Male | 18 | 17 | 35 | |
| Total | 27 | 26 | 53 | |
| age | PFNA-2 | Short PFN | | >0.05 |
| | mean 73 | mean 75.2692 | | |
| side | type | | Total | 0.893 |
| | PFNA-2 | Short PFN | | |
| Left | 13 | 13 | 26 | |
| Right | 14 | 13 | 27 | |
| Total | 27 | 26 | 53 | |
| Evans classification | type | | Total | 0.249 |
| | PFNA-2 | Short PFN | | |
| 2 | 5 | 2 | 7 | |
| 3 | 12 | 10 | 22 | |
| 4 | 9 | 9 | 18 | |
| 5 | 1 | 5 | 6 | |
| Total | 27 | 26 | 53 | |

sliding hip screw with cancellous bone grafting.

Of the 14 malalignments of more than 5 degrees that were recorded on follow up, 4 were in the PFNA-2 group and 10 were in the Short PFN group, with a prevalence of varus malalignment.

With regard to clinical outcome, the mean modified HHS in the PFNA-2 group was 71.407 (60-78) and in the Short PFN group was 78.077 (72-80), being significantly better in the Short PFN group. The Parker Palmer mobility score was 5 in 19 PFNA-2 group patients (70.4 percent) and 12 Short PFN group patients (46.2 percent), while residual hip pain was seen in 13 patients each in both the groups. However, an average of 81.11 percent of patients in the PFNA-2 group were satisfied with the results, while 77.5 percent of patients on Short PFN group were satisfied. Statistical analysis between them showed significant difference, favouring the PFNA-2 group.

Table 2: Comparison of significant outcome variables between the two groups

| | type | Mean | Standard Deviation | Standard Error Mean | t | p value |
|---|---|---|---|---|---|---|
| trauma to surgery time (days) | PFNA-2 (n = 27) | 4.333 | 3.530 | 0.679 | 0.796 | 0.432 |
| | Short PFN (n = 26) | 3.769 | 1.032 | 0.202 | | |
| operative time (minutes) | PFNA-2 (n = 27) | 38.148 | 5.855 | 1.127 | -1.786 | 0.08 |
| | Short PFN (n = 26) | 41.154 | 6.373 | 1.250 | | |
| image intensifier time (seconds) | PFNA-2 (n = 27) | 20.630 | 3.804 | 0.732 | -3.785 | 0.000 |
| | Short PFN (n = 26) | 25.885 | 6.015 | 1.180 | | |

## Discussion

Due to the increasing age of the elderly population, the incidence of hip fractures has been gradually increasing. These group of patients generally have poor bone quality, thus requiring a fixation device that provides maximum stability and minimises surgical complications. All the patients were operated within 3 to 5 days and mobilised early to prevent medical complications and improve functional outcome.

Of all the patients 85 percent had fracture due to trivial trauma, indicating poor bone quality across both the groups.

No significant difference was found in the mean operative times, attributed to single expert surgeon. However, the significantly lesser image intensifier time in the PFNA-2 group could be attributed to lesser number of cephalic screws. In PFNA-2 system, the helical blade performs both functions, compression at the fracture site for anatomic reduction and provides rotational stability, thereby preventing the need of an anti-rotation screw.

Thus by providing a more stable fixation, fewer patients with Evans 3 or 4 fractures required additional cephalic screw. There were 4 cut-in (proximal migration of he cephalic screw)and 5 cut-out in our study 2 in each group with 3 cut-outs in Short PFN group.

In all these cases the cephalic screw position was assessed using the CalTAD. A study by Nikoloski and colleagues [18] suggested to avoid a TAD <20 mm due to possible axial cut-out (medial migration) and to avoid a TAD >30 mm to avoid cephalad cut-out. All our back-outs had CalTAD > 25 mm and the cut-ins had CalTAD < 15 mm. The positioning of the lag screw or helical blade in the head of the femur is critical. CalTAD , which represents both the position and the depth the screw in the femoral neck and head, was shown to be a significant predictor of cut-out [19]. It has been shown that the placement of the lag screw inferiorly in the femoral head when using a cephalomedullary nail to treat an unstable peritrochanteric fracture results in the stiffest construct in axial and torsional biomechanical testing. Superior head lag screw placement should be avoided as this produces the least stiff construct. A simple radiographic measurement, CalTAD, provides an intra-operative method of determining optimal cephalomedullary nail lag screw position to achieve greatest construct stiffness [15]. Although it is an important predictor of cut-out, it is not the only one, as fracture pattern, fracture reduction, bone quality and age are also important predictors [19]. In addition, the cutting-in of the helical blade into the head-neck fragment could be explained due to the blockage of the gliding mechanism. Interestingly in our study the CalTAD did not decrease significantly from the time of surgery to final follow-up. However, the mean CalTAD in the Short PFN group decreased by 1.193 mm at the 12 month follow-up.

According to the Cleveland zones, there was no significant difference in implant position between the two groups. Due to the physiological 12 degrees anteversion of the neck of the femur, Cleveland zones 5, 6, 8 and 9 are in an area of no rotational force [20]. We placed most of the helical blade tips (87.05 percent) or lag screw tips (71.15 percent) in zone 5. Implant tips placed in zones 4 or 7 are, from the biomechanical point of view, in the area of rotational forces. This might account for the rotation of the head and neck fragment, resulting in cutout.

Intra-operative femoral shaft fractures may result from insufficient reaming of the intramedullary cavity. No intra-operative femoral fracture was observed in our study, due to pre-operative selection of nail of appropriate diameter.

Secondary varus malalignments occurred in fewer patients in the PFNA-2 group. This could be explained by a more accurate implant positioning of PFNA-2 with 87.05 percent patients having tip of blade in Cleveland zone 5 and better CalTAD measurements as compared to the Short PFN. The helical blade has a significantly higher torque for the rotation of the femoral head compared to the lag screw. Bone impaction around the PFNA blade could probably be the reason for the higher biomechanical stability, thus decreasing the risk of malrotation and varus collapse [21].

Clinically, despite both the groups having almost equal residual hip pain, the PFNA-2 group patients were more satisfied and had better walking ability after fracture treatment, which could be attributed to accurate implant position, more stable fixation and lower rate of varus malalignments with the PFNA-2.

We believe that the differences between the two nails may be more significant in highly osteoporotic bone of very elderly patients.

## Conclusion

According to our study, CalTAD and Cleveland zones are important indices of implant position and predictors of screw or blade migration. Patient age, bone quality and fracture pattern and quality of reduction are other predictors of migration. Optimum CalTAD should be between 15 mm and 25 mm.

The PFNA-2 seems currently to be the optimal implant, especially in very old, severely osteoporotic patients with unstable intertrochantric fractures, while Short PFN may be used in stable intertrochantric fractures inpatients with a slightly better bone mineral density.

In our opinion and according to our results, the choice of implant (type and size) should be done pre-operatively by evaluating fracture pattern and geometry, bone quality and patient age, to achieve accurate implant position, stable fixation, thereby reducing risk of malalignments and providing better clinical outcomes, considering the advantages and disadvantages of different implants.

## References


1. Kulkarni G., Limaye R., Kulkarni M. and Kulkarni S. Intertrochanteric fractures. Indian J Orthop 2006;40:16.
2. Evans E. M. The treatment of trochanteric fractures of the femur. J Bone Joint Surg Br 1949;31B:190-203.
3. Babhulkar S. S. Management of trochantric fractures. Indian J Orthop 2006;210-8.
4. Haidukewych G. J., Israel T. A. and Berry D. J. Reverse obliquity fractures of the intertrochanteric region of the femur. J Bone Joint Surg Am 2001;83-A:643-50.
5. Kyle R. F., Ellis T. J. and Templeman D. C. Surgical treatment of intertrochanteric hip fractures with associated femoral neck fractures using a sliding hip screw. J Orthop Trauma 2005;19:1-4.
6. Wolfgang G. L., Bryant M. H. and O'Neill J. P. Treatment of intertrochanteric fracture of the femur using sliding screw plate fixation. Clin Orthop Relat Res 1982;148-58.
7. Simpson A. H., Varty K. and Dodd C. A. Sliding hip screws: modes of failure. Injury 1989;20:227-31.
8. Anglen J. O., Weinstein J. N. and American Board of Orthopaedic Surgery Research C. Nail or plate fixation of intertrochanteric hip fractures: changing pattern of practice. A review of the American Board of Orthopaedic Surgery Database. J Bone Joint Surg Am 2008;90:700-7.
9. Leung K. S., So W. S., Shen W. Y. and Hui P. W. Gamma nails and dynamic hip screws for peritrochanteric fractures. A randomised prospective study in elderly patients. J Bone Joint Surg Br 1992;74:345-51.
10. Hardy D. C., Descamps P. Y., Krallis P., Fabeck L., Smets P., Bertens C. L., et al. Use of an intramedullary hip-screw compared with a compression hip-screw with a plate for intertrochanteric femoral fractures. A prospective, randomized study of one hundred patients. J Bone Joint Surg Am 1998;80:618-30.
11. Megas P., Kaisidis A., Zouboulis P., Papas M., Panagopoulos A. and Lambiris E. [Comparative study of the treatment of pertrochanteric fractures--trochanteric gamma nail vs. proximal femoral nail]. Z Orthop Ihre Grenzgeb 2005;143:252-7.
12. Takigami I., Matsumoto K., Ohara A., Yamanaka K., Naganawa T., Ohashi M., et al. Treatment of trochanteric fractures with the PFNA (proximal femoral nail antirotation) nail system - report of early results. Bull NYU Hosp Jt Dis 2008;66:276-9.
13. Gadegone W. M. and Salphale Y. S. Short proximal femoral nail fixation for trochanteric fractures. J Orthop Surg (Hong Kong) 2010;18:39-44.
14. Cleveland M., Bosworth D. M., Thompson F. R., Wilson H. J., Jr. and Ishizuka T. A ten-year analysis of intertrochanteric fractures of the femur. J Bone Joint Surg Am 1959;41-A:1399-408.

15. Kuzyk P. R., Zdero R., Shah S., Olsen M., Waddell J. P. and Schemitsch E. H. Femoral head lag screw position for cephalomedullary nails: a biomechanical analysis. J Orthop Trauma 2012;26:414-21.

16. Parker M. J. and Palmer C. R. A new mobility score for predicting mortality after hip fracture. J Bone Joint Surg Br 1993;75:797-8.

17. Harris W. H. Traumatic arthritis of the hip after dislocation and acetabular fractures: treatment by mold arthroplasty. An end-result study using a new method of result evaluation. J Bone Joint Surg Am 1969;51:737-55.

18. Nikoloski A. N., Osbrough A. L. and Yates P. J. Should the tip-apex distance (TAD) rule be modified for the proximal femoral nail antirotation (PFNA)? A retrospective study. J Orthop Surg Res 2013;8:35.

19. Kashigar A., Vincent A., Gunton M. J., Backstein D., Safir O. and Kuzyk P. R. Predictors of failure for cephalomedullary nailing of proximal femoral fractures. Bone Joint J 2014;96-B:1029-34.

20. Yang Y. H., Wang Y. R., Jiang S. D. and Jiang L. S. Proximal femoral nail antirotation and third-generation Gamma nail: which is a better device for the treatment of intertrochanteric fractures? Singapore Med J 2013;54:446-50.

21. Al-Munajjed A. A., Hammer J., Mayr E., Nerlich M. and Lenich A. Biomechanical characterisation of osteosyntheses for proximal femur fractures: helical blade versus screw. Stud Health Technol Inform 2008;133:1-10.

Conflict of Interest: NIL
Source of Support: NIL

## How to Cite this Article

Kulkarni SG, Rathi PP, Kulkarni GS, Saxena SP, Dixit PP. Unstable Intertrochanteric fractures: Comparison of Proximal Femoral Nail Anti-rotation 2 and Short Proximal Femoral Nail. Journal of Trauma and Orthopaedic Surgery July - Sep 2016;11(3):12-18.