Original Article The Journal of Maharashtra Orthopaedic Association 2013;8(4):10-16

Proximal femoral nail for treatment of Unstable Trochanteric fractures, Review of Results in 60 cases

Sunil V. Patil[1], Bhupinder Nath Singh[1]

Abstract

Introduction :- To review the outcome of 60 patients treated with a proximal femoral nail (PFN) for Unstable trochanteric fractures from Jan 2010 to Dec 2011.

Methods: 27 men and 33 women aged 28 to 90 (mean, 63) years with Unstable trochanteric fractures underwent PFN fixation using an cephallo-medullary nail, a lag screw, and a hip pin & Interlocking Bolts. Fractures were classified according to the AO system; the most common fracture type was A3 (n=35), followed by A2 (n=25) with Left sided(65%) Predominance. 15(25%) Fractures required to be openly reduced & fixed. All Fractures were satisfactorily Fixed using standard long or Short PFN depending on Fracture architecture & results were analysed. Average follow-up was for 15 months. Average Operating time was 90 min with average Blood Loss of 150 cc .

Results: 90% of lag screws were optimally placed with well reduced fracture. 58(95%) united within average of 15 weeks(12- 18 weeks). Fractures in Males united slightly earlier than the Fractures In Females .2 cases had breakage of Implants & hence Non Union occurred. Average shortening was 2cms & No External Rotation Deformities were witnessed. 54 cases (90%) had good to Excellent results, 6 cases (10%) had poor results ,either Infection (3) , Breakage of Implants (2) & 1 had gap Nonunion.

Conclusion: PFN is an useful & reliable Implant for the treatment of Unstable trochanteric Fractures at any age group.

Key words: Proximal femoral nails; unstable Trochanteric fractures; lag screw.

Introduction

Subtrochanteric fracture of the femur is a variant of peritrochanteric fracture of the femur [1]. It lies in the area which is 5cm below the lesser trochanter. It may extend proximally into the intertrochanteric area and distally upto the isthmus of the shaft of the femur [2, 3]. Its incidence is much lower than that of the intra and extra capsular fracture of the neck of the femur. The incidence usually is six per 1 lack population per year, with a female preponderance [4]. Parker et al. reviewed the epidemiology of unstable trochanteric fracture of the femur and showed that it accounted for 3.9% of all the proximal femoral fractures and that the average age was 74 yrs [5]. It is common in older patients after low energy trauma along with osteoporosis and in younger patients with high energy trauma [6]. This area is also the commonest site for pathological femoral fractures (17%) due to metastatic deposits from the lung, breast, prostate, myeloma and Paget's disease [4].

The mechanism of the injury is fall and direct lateral hip trauma, road traffic accidents, axial loading, fall form height and gunshot injury [7]. Unstable -trochanteric fracture is one of the most difficult fractures to treat and treatment failure is common for it, due to the complications of mal-union, non-union, shortening, angular deformity and rotational mal-union (Waddel 1979, Mullaji and Thomas 1993) [8,9]. It is associated with a mortality or morbidity of 20% because of the maximum stress which is exerted at the fracture site during the activities of daily living, as compared to the rest of the femoral fractures [4].An appropriate implant for internal fixation and implant failure remains debatable.

Subtrochanteric fracture of the femur is a variant of peritrochanteric fracture of the femur [1]. It lies in the area which is 5cm below the lesser trochanter. It may extend proximally into the intertrochanteric area and distally upto the isthmus of the shaft of the femur [2, 3]. Its incidence is much lower than that of the intra and extra capsular fracture of the neck of the femur. The incidence usually is six per 1 lack population per year, with a female preponderance [4]. Parker et al. reviewed the epidemiology of unstable trochanteric fracture of the femur and showed that it accounted for 3.9% of all the proximal femoral fractures and that the average age was 74

[1]Dept. of Orthopaedics, Associate Proffessor , Bharati Vidyapeeth Deemed University Medical College & Hospital,Sangli. India.

Address of Correspondence:

Dr Sunil V. Patil. Associate Proffessor , Bharati Vidyapeeth Deemed University Medical College & Hospital,Sangli. India.

Mail: nilpa18nov@yahoo.com

yrs [5]. It is common in older patients after low energy trauma along with osteoporosis and in younger patients with high energy trauma [6]. This area is also the commonest site for pathological femoral fractures (17%) due to metastatic deposits from the lung, breast, prostate, myeloma and Paget's disease [4].

The mechanism of the injury is fall and direct lateral hip trauma, road traffic accidents, axial loading, fall form height and gunshot injury [7]. Unstable -trochanteric fracture is one of the most difficult fractures to treat and treatment failure is common for it, due to the complications of mal-union, non-union, shortening, angular deformity and rotational mal-union (Waddel 1979, Mullaji and Thomas 1993) [8,9]. It is associated with a mortality or morbidity of 20% because of the maximum stress which is exerted at the fracture site during the activities of daily living, as compared to the rest of the femoral fractures [4].An appropriate implant for internal fixation and implant failure remains debatable.

Patho-physiology

The muscles of the proximal femur displaces the fracture considerably and most of the bone is cortical. Healing in this region is achieved through a primary cortical healing and it is slow to consolidate [10]. The axial loading forces through the hip joint create a large moment arm with large lateral tensile and medial compressive loads. The muscle forces of the hip also play torsional and rotational shear forces. This area is highly vascular and so the bleeding in the thigh is common, leading to shock and the compartmental syndrome. During normal activities, 6 times of the body weight is transferred across this region [11].

Biomechanical Studies

During weight bearing, mechanical stress acts on the femur. The compression stress is >1200 lb/sq inch in the medial Subtrochanteric area and 3cm distal to the lesser trochanter. The lateral tensile stress is 20% less at 1000 lb/sq inch [4]. There is continuous stress on the implant system, even during bed rest .So, the attention of the medial cortical buttress is required to minimise the implant failure.

Higher forces are generated with eccentrically placed devices such as plates and screws, as compared to the centromedullary devices. Rotational shear forces may lead to implant failure due to cyclical loading. Plate and screw devices restored approximately 40% of the normal femoral torsional stiffness. Interlocking nails are better in bending stiffness than the hip compression screws. There was a marked improvement in the bending stiffness, torsional stiffness and the axial load to failure with the closed section interlocking devices [12]. Bending forces cause the medial cortex to be loaded in compression and the lateral cortex to be loaded in tension. The compression forces are much higher than the tensile forces and they are therefore mandatory in restoring the medial cortex stability. 2mm separation of the medial cortex will lead to medial collapse and lateral plate bending.More the communition,lesser the bio-mechanical stability and more the bio-mechanical loading, more the communition. When the medial cortical support is inadequate, the internal fixation devices act as tension band in the lateral femoral cortex and the loads are concentrated in one area of the implant, thus resulting in implant failure or loss of fixation [13].

Relevant Anatomy

The Subtrochanteric region is a cortical bone. Femoral head antiverted 13°, piriformis fossa at the base of the neck. The lesser trochanter is posterior medial and the iliopsoas muscles are inserted on it, which flexes the proximal fracture fragment. The gluteus medius and the minimus abduct and externally rotate the proximal fragment. The adductors pull the distal fragment medially and upward. The muscles are highly vascularised and can lead to haemorrhage during injury or surgical procedures. The vastus lateralis is splinted close to the perforating branches of the profunda femoris artery, which may get injured, leading to bleeding with difficult exposure [14].

Classification

Because of the fracture configuration and the patient heterogeneity no universally accepted classification exists [14].Many classification systems have been proposed, but AO (1980) and Russell and Taylor's(1992) classifications have been used most commonly. The treatment of the unstable trochanteric fracture has been revolutionised by the development of the long reconstruction nail which was previously difficult to treat. The Russell and Taylor classification has Type I and Type II fractures with sub groups A and B in both. The Type I fracture does not extend into the piriformis fossa. The Type II fracture extends to the greater trochanter and it involves the piriformis fossa. The Type IA fracture line is below the lesser trochanter and the Type IB extension involves the lesser trochanter. The Type IIA fracture extends to the piriformis fossa and the Type IIB fracture involves the piriformis fossa and it extends to the medial femoral cortex and the loss of continuity of the lesser trochanter [1]. The classification is biomechanically

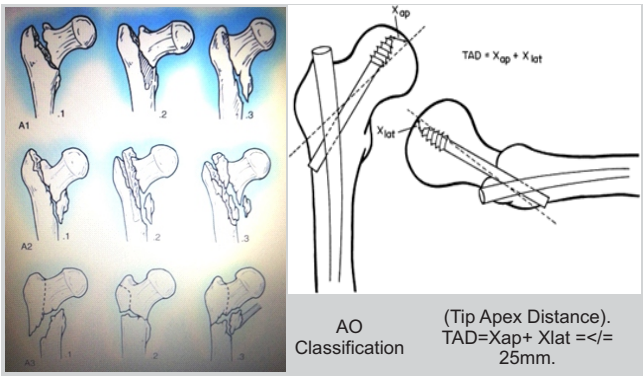

AO Classification

(Tip Apex Distance). TAD=Xap+ Xlat =</= 25mm.

Fig Showing Patient Placement on Fracture Table after achieving acceptable Reduction, alignment , & Rotation in AP & Lat.

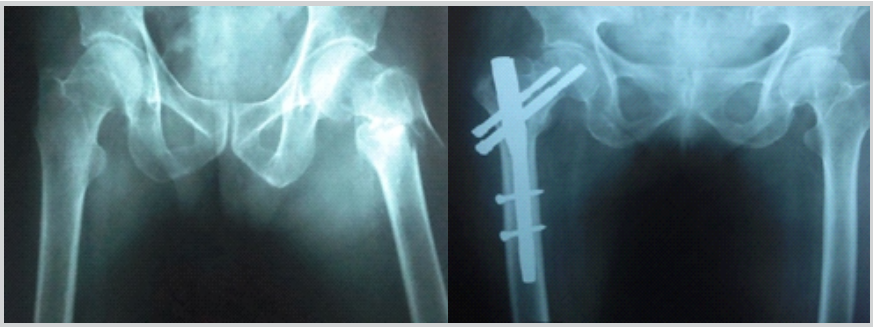

Fig Showing A3 Fracture fixed excellently

sound, it fulfils the criteria best and it was designed to allow the selection of the technique of the internal fixation that produces the most biomechanically sound reconstruction [4]. The extent of involvement of the lesser trochanter, the greater trochanter and the piriformis fossa were taken into consideration.

AO classification is based on the number of fragments and the location and configuration of the fracture line. It classifies the fractures as Type A to type C [15].

Treatment Protocol

Surgical stabilization is the treatment of choice, but it is technically challenging. The treatment goals are – anatomical alignment, restoration of the length, rotation with good fixation, prevention of the varus deformity, maintainence of the lever arm of the abduction muscle and encouraging early mobilization and rehabilitation. Role of the bone graft: is controversial & should be complimentary if excessive void is present but not compulsory. It helps in protecting the fixation device from the varus deformity which is caused due to lack of medial cortical continuity [2].

Implants which are used conventionally:

1. Intramedullary – Centromedullary nail (conventional interlocking nails) and Cephalomedullary (PFN/IMHS).

2. Plate osteosynthesis – 135° screw plate (DHS), 95° dynamic condylar screw (DCS) and 95° angle condylar blade plate. Advantages of the IM devices over the Nail blade plate [13]:

1. Shorter lever arm – so it is biomechanically stronger and the stress on the implant is less

2. Load sharing device instead of load bearing –less stress on the implant

Fig Showing good Clinical Results in 80 year old lady

3. Can be introduced without exposing the fracture site –fracture haematoma not disturbed, hence chances of the union are more and faster.

4. Transmits weight close to the calcar and has greater mechanical strength.

5. Distal locking screw provides length and rotational control and early weight bearing.

The variables which have to be considered while making the choice of the implant are:

1. Fracture extension to the piriformis fossa-common nail entry portal.

2. Continuity of the lesser trochanter.

The predisposing risk factors are: Degree of comminution, in-volve ment of the lesser and greater trochanter and the severity of osteoporosis.

Advantages of the Medullary technique: Retained blood supply to the fragment, less operative blood loss and less disruption of the fracture environment and cephalomedullary nailing allows length and rotational control.

Treatment algorithm: An appropriate implant for internal fixation is still debatable [3].

Type A :Conventional sliding Hip device (DHS).

Type B: DHS or Long cephalomedullary reconstruction nail.(PFN).

Type C: PFN is an Universal choice.

Material and Method

A total of 60 cases of unstable trochanteric fracture of the femur were Treated in Bharati Vidyapeeth Medical

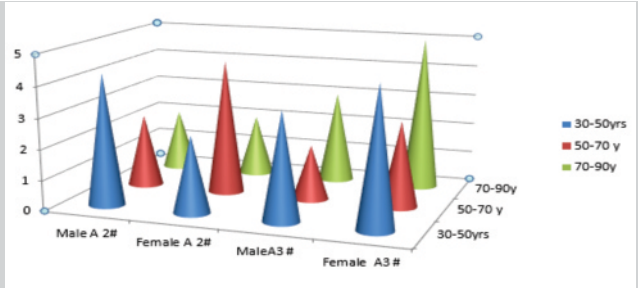

Figure 1: Showing Age & Sex Wise & Type of Fracture Incidence Of Trochanteric Fractures In our Series. Max Incidence from 7th & 8th decades.

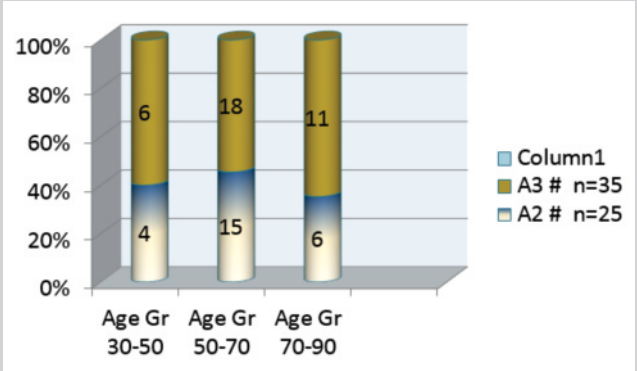

Figure 2: Type Of Fracture & Age Gr wise Distribution.

College & Hospital, Sangli, in the Department of Orthopaedics from Jan 2010 to July 2011. Out of these 60 patients, 27 were males and 33 were females. Their ages ranged from 30 to 90 years (average age 65 years). We used the AO classification for simplicity and it is the one which is the currently mostly used classification . There were n=25 A2 types of fractures- & n= 35 A3 Type of fractures. Of these, 34 were left sided and 26 were right sided.

The mechanism of the injury included 28 fractures were due to motor vehicular injury and 32 were due to low energy trauma.

One patient with a pathological fracture had a Secondary deposit was fixed with PFN . 15(25%) cases required open reduction as they were difficult to negotiate & Reduce. No bone grafting was done in any of the cases. Standard 180m PFN was passed from the tip of the trochanter after reduction was held by assistant & ext devices(Reduction Clamps , Steinman pin etc). & PFN was passed & Proximal Hip screw & Hip Locking bolt was passed under IITV & Lengths were checked & as far as possible their tips were collinear. Reduction & Fixation was checked in AP & Lat Views before closure over the drain & Skin was closed .

Cerclage wire was used in twelve(12) cases. As per our protocol, we removed the suture after 14 days. We allowed the operated cases to stand and walk with non weight bearing and with bi-lateral axillary crutches for 2 weeks to

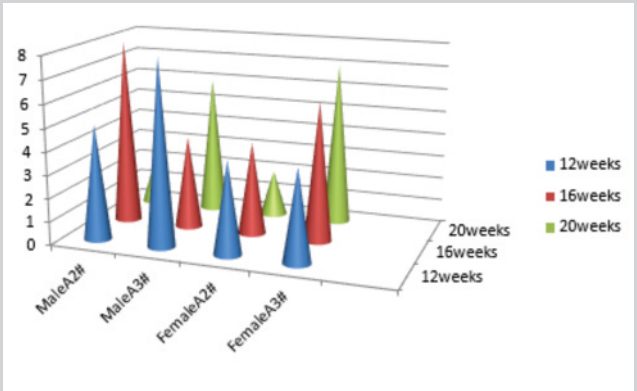

Figure 4: Showing Results comparing Type Of Fracture with Sex Incidence & Time taken for Union in Weeks

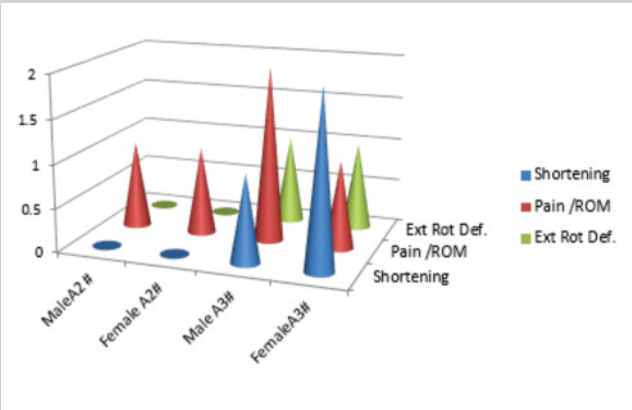

Figure 3: Showing Incidence Of Percentage of Complications as compared to Type of Fracture In Both Sexes.

3 weeks. After 3 weeks, we allowed partial weight bearing, followed by full weight bearing after 10-12 weeks for PFN fixation & as per radiological union.

Partial weight bearing was advised when the patient could tolerate the pain, with bi-lateral axillary crutches. Full weight bearing was delayed for 3 months. Radiographs were taken at 3 weeks, 6 weeks, 3 months, 6months and 1 year. Strengthening exercises for the quadriceps, hamstrings and the gluteal muscles were done in bed and out of bed under the supervision of a physiotherapist. The range of motion of the hip and knee was examined during the follow-ups. The post operative patients were followed up for 15 -18 months.

Result

The distribution of the age, sex and the sides are shown in the [Table/Fig-1]. The average age of the female patients was 65 years and it was 58 years for the males. One patient with pathological fracture was a female of 70 years of age .

Radiologically, the average time of the union for the PFN, was 3- 3.5 months .ROM of the hip in the case of pathological fracture was mild to moderate pain with restriction up to 7 months and in the case of other PFN

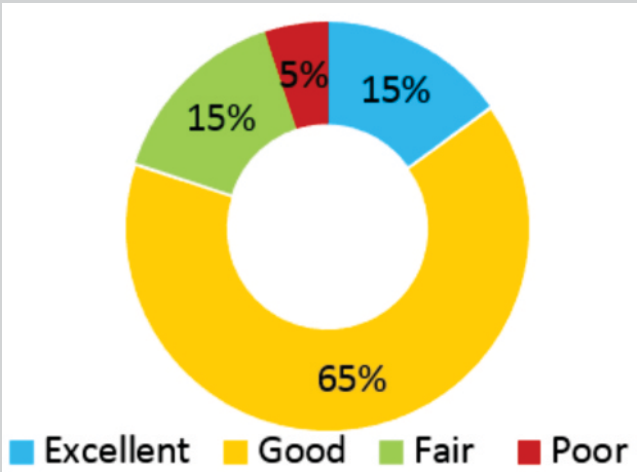

Figure 4: Showing Results comparing Type Of Fracture with Sex Incidence & Time taken for Union in Weeks

Figure 6: Showing A3 fracture in 70 year old man with excellant Fixation & good Clinical Result.

cases , there was mild restriction of hip up to 2 months. There was shortening of 2 cm in communited subtrochanteric Fracture in 3 cases. The overall functional outcome varied from good to excellent in all our cases. (80 %) Fair in 15 % & Poor 5% because of Implant failure & Refall was seen in 3 patients.

Discussion

In modern trauma care, there is no role of conservative treatment, as was advocated by Delee et al [16].The treatment of Unstable trochanteric fractures was mainly focussed on ORIF by using vari-ous implants with or without bone graft and cerclage wiring [7].

Plating was blamed for extensive surgical exposure, severe soft tissue damage, severe blood loss, non-union and implant failure. Eccentrically, plating usually resulted in fatigue breakage due to a mechanical load shearing effect. Intra-medullary nailing had a more biological and mechanical advantage and it was accepted as an implant of choice without the complications of cut out, breakage of the implant or peri-implant fracture. Osteosynthesis with PFN is gaining popularity nowadays [3].Most important for success is the correct entry point; the laterally shifted entry point should be on the tip of the greater trochanter in the AP view and in line in the centre of the femoral canal in the lateral view & 6 degrees valgus to the mechanical axis of shaft of femur.. Long/Spiral fracture needs open reduction with cerclage wiring.

In our series, we used cephalomedullary PFN for more stability, strength, more rotational stability, lesser Exposure, therefore less blood loss & decreased operative time thereby reducing the patient morbidity.

Long PFNs, as implants of choice, healed the fractures uneventfully and the walking and squatting abilities were completely restored with the bone union. The lag screw of the PFN should be placed in the lower part of the femoral neck, close to the femoral calcar, with the screw tip reaching the subchondral bone, 5-10 mm below the articular cartilage in the AP view. In the lateral view, it should be placed in the centre of the femoral neck. The timing of the weight bearing will be partial up to 6 weeks, to allow callus formation. Full weight bearing can be advised after 12 weeks if the lesser trochanter is attached to the proximal fragment. The PFN is preferred because there is a better control of the rotation and the length can be confirmed by biomechanical and clinical studies.

Load sharing devices allow compression at the fracture site, with good results. Intramedullary fixation of Unstable trochanteric fractures with the Proximal Femoral Nail (PFN) – is a reliable implant, leading to good union and less soft tissue damage. It has a biomechanical advantage, but it is technically demanding operation.

Showing Good Clinical Result in a 70 year old man. fig b). Showing Cerclage wiring done (in 15 cases). / Showing good Fixation in Communited A3 # & excellent Clinical Result

Fig showing good Fixation & excellent Clinical Result. Fig b.Showing A3 type Fracture In a 75 year Old lady.

Fig :-Showing good Fixation & excellent Clinical Result

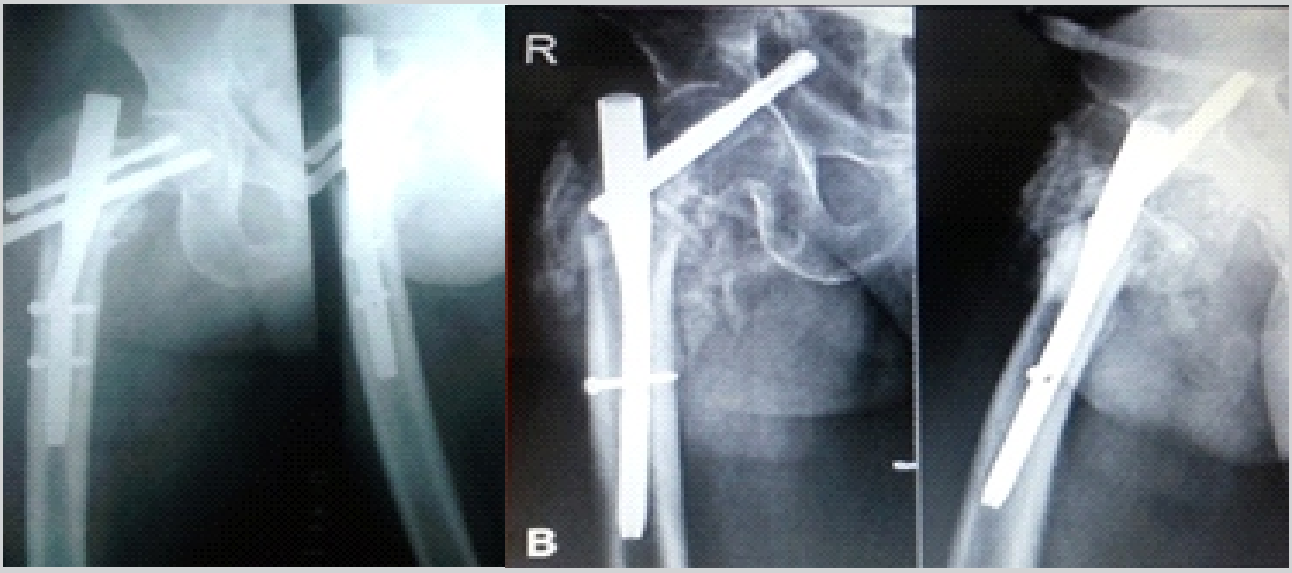

Fig A showing breakage of PFN at proximal Locking Bolt, B). Showing penetration of Helical screw

Long PFN fixation, irrespective of the degree of proximal comminution, is preferable and the cephalomedullary nail with a greater lateral offset, allows the entry portal more laterally, irrespective of the involvement of the piriformis fossa. It is also clear that the overall results of IM nailing are better than those of plate fixation, according to Parker et al (1997) [3].

Intramedullary Hip screw (IMHS) is a better design; it buttresses the head and neck, temporarily substituting for the unstable, large posterior medial fragment. Because of the femoral re-fracture rates in zickel nail and the femoral shaft fractures in gamma nail, they are discontinued. The cut-out failure of the Ross Taylor nail is a well recognized complication. A long reconstruction nail with a single side arm still remains one of the optimum methods of fixation of Unstable trochanteric fractures [4]. A Helical Screw System has been recently been introduced but it is very costly & technically demanding Instrumentation set are required & is also not free from cutout complications.

COMPLICATIONS :- Like non-union, Varus Deformity, infection, and heterotrophic ossification were not encountered in our series, expect for the mild to moderate painful restriction of the ROM of the hip in one case, 2 cases of Implant Breakages in our early days of experience leading to some External rotation Deformity , and the shortening of 2 cm in 2 cases with Severe Communition were noted in our series.

Conclusion

In our study, there was big group of patients and there were no drop out cases in the follow up. Our experience of fixation with PFN showed that PFN gave a better control of the rotation, length and proximal purchase. The load shearing nature of this implant which allowed compression at the fracture site and even in the osteoporotic bone and its cephalomedullary location had decreased moments as compared to the plate.

So, we recommend the cephalomedullary PFN as one of the better methods of fixation . Bone grafts should not be a routine procedure except with severe comminuted fracture, with lack of posterior-medial cortical continuity. Despite the introduction of newer designs, better quality of the implant and improvement in the technique, fixation is still a challenge for the orthopaedic surgeons. Search for an ideal implant and an ideal method of fixation in this complex situation still needs to be done Research should go on.

References

1. *Canale ST, Beaty JH, Fractures and Dislocations of the Hip. In: Lavelle DG Editor. Campbell's operative orthopaedics. 11th ed. Mosby Elsevier: 2007; 3262-70.*
2. *Clifford R. Subtrochanteric Fracture. Wheeless Text Book of Ortho paedics. [last updated: 30/06/2011*
3. *Jiang LS, Shen L, Dai LY. Intramedullary fixation of Subtrochanteric fractures with a long proximal femoral nail or a gamma nail: Technical notes and preliminary results. Ann Acad Med Singapore. 2007; 36:821-26.*
4. *Court-Brown C M, Alho A, Robinson CM. Subtrochanteric fracture. In: Court-Brown CM Editor. Musculoskeletal Trauma Series Femur, Arnold, 2002; 88-95.*
5. *Parker MJ, Dutta BK, Sivaji C, Pryor GA. Subtrochanteric fracture of the. Injury1997; 28: 91-95.*
6. *Bucholz RW, Heckman JD, Court-Brown, Charles M. Subtrochanteric Fractures. In Leung KS Editor. Rockwood and Green's Fractures in Adults. 6th ed. Lippincott Williams and Wilkins; 2006;1828-44.*
7. *Rijal KP, Manandhar RR, Pandey BK. Subtrochanteric fractures of the femur: Result of ORIF at KMCTH. Kathmandu University Medical Journal. 2007; 5(18):161-65.*

8. Waddell JP. Subtrochanteric fracture of the femur: a review of 130 patients. J Trauma1979; 19: 582-92.

9. Mullaji AB, Thomas TL. Low energy Subtrochanteric fracture in an elderly patient: result of fixation with a sliding screw plate. J Trauma 1993; 34: 56-61.

10. Perren SM. Evolution of the internal fixation of long bone fractures. The scientific basis of biological internal fixation: choosing a new balance between stability and biology. J Bone Joint Surg Br. Nov 2002; 84(8):1093-110. [Pubmed].

11. Bergmann G, Graichen F, Rohlmann A. Hip joint loading during walking and running, as was measured in two patients. J Biomech.Aug 1993; 26(8):969-90. [Pubmed].

12. Crenshaw A. Fractures of the Hip and Pelvis. In: Russel TA Editor. Campbell's operative orthopaedics. 8th ed.USA, Mosby; 2007; 3262-70.

13. Taneja DK. Subtrochanteric fracture-Recent advances in management. In Taneja DK. Recent trend in Fracture management. 2001.p39-43.

14. Jaffe W L, Editor. Subtrochanteric Hip Fractures. Medscape reference. [Update: Jul14, 2010]. [15] Seinsheimer F III: Subtrochanteric fractures of the femur, J Bone Joint Surg 1978; 60A:300.

15. DeLee JC, Clanton To, Rockwood CA Jr. Closed treatment of Subtrochanteric fracture of the femur in a modified cast-brace. J Bone Joint Surg Am 1981; 63:773-79.

Conflict of Interest: Nil

Source of Support: Nil

How to cite the article:
Patil SV & Singh BN. Patil SV & Singh BN, Proximal femoral nail for treatment of Unstable Trochanteric fractures, Review of Results in 60 cases. The Journal of Maharashtra Orthopaedic Association. Oct-Dec 2013; 8(4):10-16