Journal Of
Maharashtra Orthopaedic Association
September - 2005

Treatment of Tibial Plateau Fractures by Ilizarov Technique

Dr. Ruta Milind Kulkarni, Dr. G. S. Kulkarni M.S.(ORTH)
Post Graduate Institute of Swasthiyog Pratishthan,
Miraj.
Phone : (91 / 233) 22-2590, -3268 **Fax :** 3394

Key Words

Tibial plateau fractures - intraarticular fractures - Percutaneous screw fixation - ilizarov fixator - Restoration of articular surface - Early function

Abstract

Tibial plateau fractures type 4, 5 & 6 as classified by Shartzker (8) are quite complex and associated with other injuries like subluxation and meniscal injuries. We have treated 56 such fractures by a new technique. We fix the fracture by one or two 6.5 mm lag screws inserted percutaneously and further stabilize it by Ilizarov ring fixator. Reduction of fracture is done by longitudinal traction on a fracture table. Two or three 6.5 mm. lag screws are inserted percutaneously to compress the major fragments. A three-ring ilizarov frame is applied. Olive wires are used to reduce and compress posterolateral and / or posteromedial fragments. The frame is extended to the femur in instances of subluxation of the knee joint, ligamentous injuries, and associated femoral condylar fractures. Objective is restoration of articular surfaces and early functional treatment. Between 1991-1997, 56 patients were operated on. Average follow-up was 3 years. Union occured in all. Six patients showed a varus deformity of 5-10° and one a varus deformity of 15°; four patients had an extension lag between 5-10°. A minor pin tract infection was observed 20 times and a major pin tract infection three times neccessitating pin removal. One patient who suffered a compound fracture complicated by aseptic arthritis eventually required an arthrodesis.

Applying the score of the American Knee Society, an excellent result was obtained 20 times, a good result 28 times, a fair one four times, and a poor one four times.

Open, infected tibial plateau fractures are not treated by this technique. Relative contraindications are Schatzkar type 1, 2 and 3 fractures of the tibial plateau which can be treated by simpler methods.

Introductory Remarks

Complex tibial plateau fractures such as bicondylar fractures extending into the metaphysis and deaphysis with separation from the shaft are extremely difficult to treat. These fractures are often associated with ligamentous and meniscal tears and injuries to the soft tissue envelope. Optimal treatment of intraarticular fractures of the tibial plateau requires anatomic reduction of the articular surface, proper axial alignment, stable fixation, sometimes arthrodiastasis and early mobilization. The choice of treatment is faciliated by Schtzker's classification of these fractures [8] (Figure 1).

Although Apely [1, 2] has suggested the use of skeletal traction for high-energy bicondylar fractures, these modes of treatment do not allow to maintain adequate fracture reduction. Cast bracing allows early range of motion exercises, but results are Poor [5]. Neither treatment allows to achieve anatomic reduction necessary for the prevention osteoarthritis.

Unilateral external fixation, on the other hand, has proven to be an effective method of treating these

fractures, but fails to reduce depression fractures. Even the combination of minimal internal fixation with unilateral external fixation [3] does not allow to treat condylar comminution adequately on account of the large diameter of the half pins and the poor purchase of pins in the metaphyseal cancellous bone and in the small fragments Although Apley [1, 2] has suggested the use of skeletal traction for high-energy bicondylar fractures, these modes of treatment do not allow to maintain adequate fracture reduction. Cast bracing allows early range of motion exercises, but results are poor [5]. Neither treatment allows to achieve anatomic reduction necessary for the prevention of osteoarthritis.

Figures 1 to 1f

Classification of Tibial Plateau fractures according to Schartzkar [8].

a) Type 1, Pure cleavage of lateral plateau.

b) Type 2, Cleavage combined with depression.

c) Type 3, Pure central depression.

d) Type 4, Isolated fracture of medial tibial plateau.

e) Type 5, Bicondylar fracture.

f) Type 6, Bicondylar fracture associated with Transverse or oblique fracture through Metaphysis.

Advantages

- Reduction of subluxation of knee joint achieved by spanning the fixator across the knee joint.

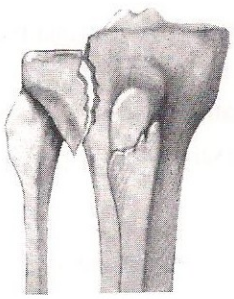

Figure 1a

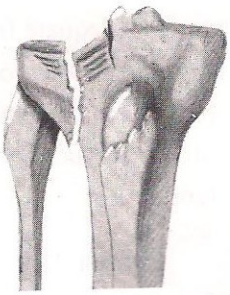

Figure 1b

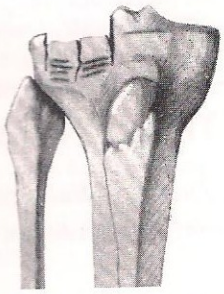

Figure 1c

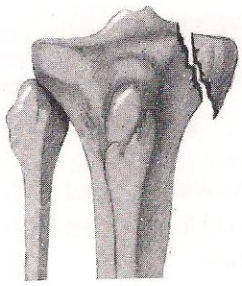

Figure 1d

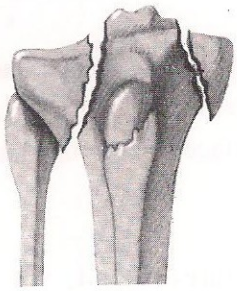

Figure 1e

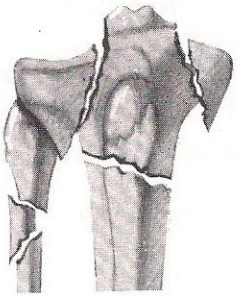

Figure 1f

- Arthrodiastasis of knee joint can be achieved : arthrodiastasis means slow distraction of the joint by spanning the apparatus across the joint and using hinges, placed at the center of rotation of the knee joint. Its goal is prevention of arthrofibrosis. The later may result in stiffness of the joint. Arthrodiastasis causes elongation of capsule and ligaments and is indicated in the presence of serve damage and comminution of the articular surface associated with ligamentous injury; arthrodiastasis leads to an increased mobility of the joint.

- Early range of motion exercise : movements can be started on day 1 by applying hinges at the center of rotation of the knee joint.

- Ilizarov fixator with minimally invasive percutaneous internal fixation, allows a stable reduction, limiting additional soft tissue trauma. [4]

- Early partial weight bearing.

- Superior results of Ilizarov technique in comparison with other treatment modalities such as open reduction and internal fixation with plates and screws which may be associated with serious complications (infection, osteomyelitis, and soft

tissue damage) and poor results [6].

- Use of olive wires to reduce not only displaced posteromedial and posterolateral fragments but also small fragments of the tibial plateau.

Disadvantages

- Bulky apparatus.

- Pain.

- Frequently, poor patient compliance.

- Risk of pin tract and joint infection.

- High Cost.

Patient Information

- Possibility of pin tract infection.

- Risk of varus deformity.

- Risk of fixed flexion deformity.

- Risk of nerve damage (peroneal nerve).

- Risk of injury to structures lying posterior to the knee (during reduction of posteromedial and posterolateral fragments).

- Risk of posttraumatic osteroarthritis.

Preoperative Work Up

- Anteroposterior (AP), lateral, emdial and lateral oblique radiographs, necessary to assess the fracture pattern.

- If available, a CT should be done.

- Make a drawing based on radiographs.

- Preoperative construction of frame.

Surgical Instruments

- Bone Set.

- Ilizarov rings.

- Olive wires.

- Orthofix half pins.

- Rancho cubes.

- 6.5 mm. Lag screws.

Anesthesia and Positioning

- General anaesthesia.

- Supine.

- Positioning on a fracture table.

- Image intensifier.

- Prepping of knee and of ipsilateral iliac crest if bone grafting is anticipated.

Surgical Technique

Figures 2 to 7

Longitudinal traction under Radiographic control a satisfactory reduction is obtained in the majority of patients. It is regarded successful even

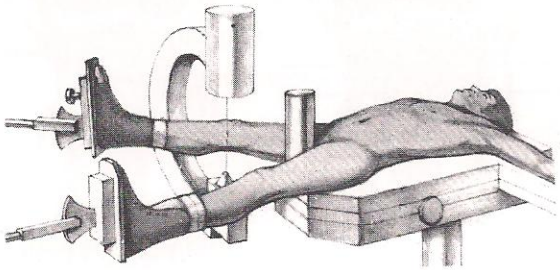

Figure 2

in the presence of a residual displacement of fragments of less than 3 mm. as judged with image intensification at different angles.

Figures 3a to 3d

a) Schatzker type 5 fracture of the tibial plateau. Note the comminution.

b) Reduction of fragments after traction. The displacement is less than 3 mm. And judged acceptable.

c) Lag screw fixation through a mini-incision.

The scres are inserted from medial to lateral under image intensification. The fragments are compressed.

d) Olive wires in opposite directions one from the medial side and one from the lateral side; they help to stabilize the fragments,. expecially smaller ones. If properly placed, they do not interfere with the screws. If possible, the screws and wires should

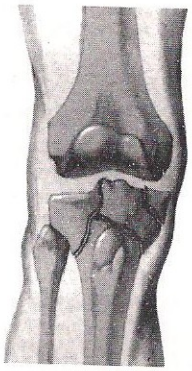

Figure 3a

Figure 3b

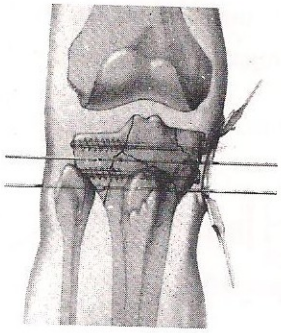

Figure 3c

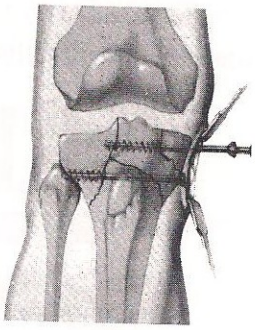

Figure 3d

lie at least 2 mm. Distal to the subchondral bone to ensure extraarticular passage, thus avoiding joint penetration.

Figures 4a and 4b

a) Posterolateral and posteromedial fragments,

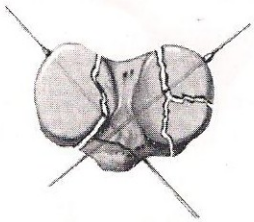

Figure 4a

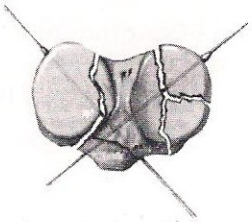

Figure 4b

difficult to reduce, can be properly positioned by olive wires,

b) Reduction through tensioning of olive wires.

Figures 5

Three-ring construction of the ilizarov frame for a Schtzker type 5 tibial plateau fracture.



Figure 5

The small wire of the proximal ring should be inserted distal to the percutaneous scres. For the proximal 1 ring, three or four olive wires are used. The number and placement depend of the number and location of fragments. If possible, one of these wires should be mounted on a post. In addition at the middle and distal ring one half pin is used to increase stability. At the middle ring, a wire is passed from a point 1 cm. Lateral to the tibial crest; it exits just anterior to the posteromedial border of the tibia.

Figure 6

In instances of a subluxation of the knee joint associated with the fracture of the tibial plateau, the frame is extended to the femur. Each ring is fixed with two half pins. The pins are passed between the quardriceps muscles, converging at tn angle of 35° in the frontal plane. The

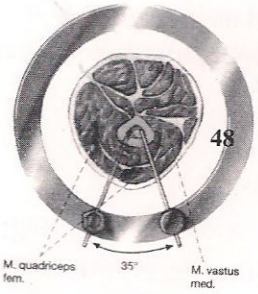

Figure 6a

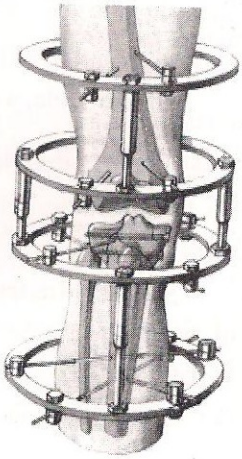

Figure 6b

subluxation is now reduced. The knee can also be distracted by 12 mm. And kept distracted till the femoral frame is removed (see also figure 8).

Indications of extension of the frame to the femur :

- Subluxation of the knee joint.

- Severe ligamentous injury. This can be diagnosed during surgery once the fragments of the tibial plateau fractures have been reduced and stabilized by lag screws and ilizaror frame with olive wires. Thereafter, valgus, varus and anterior drawer tests are done.

- Associated fractures of one or both femoral condyles.

- Depression of the tibial plateau : treatment by elevation and bone grafting. ***Figure 7***

Figure 7

Impaction of a fragment of the upper tibial end into cancellous bone. This fragment is difficult to reduce with traction alone. A window is made in the cortex, and the fragment is elevated with an impactor. The defect is filled with cancellous bone graft harvested from the iliac crest.

If indicated, distraction up to 12 cm. can be performed and kept until the femoral part of the frame is removed.

Postoperative Management

- The femoral part of the frame is kept for 4-8 weeks only. Daily dressing of pin sites is done. Prevention of equinus deformity is done by application of a plastic foot plate with rubber bands and by manually dorsiflexing the foot repeatedly. Early range of motion exercises is started in patients with stable fractures. Partial weight bearing is started after 4-8 weeks depending on the stability of the fracture. Usually, full weight bearing is allowed by 12 weeks. The frame is removed after 12-16 weeks.

Errors, Hazards, Complications

Pin tract infection :

- Soft tissue inflammation is treated with oral antibiotics and proper wire tensioning.

- Soft tissue infection is treated with local antibiotic solution 100 mg/ml of cefazolin injected along the pin tract and a course of oral antibiotics is given.

- Bone infection : need for replacement of offending wire.

- Acute joint infections : debridement and suction irrigation for 24 h and antibiotic therapy based on culture and sensitivity tests.

- Varus deformity : a long film is taken to assess the degree of varus deformity. Immediate postoperative correction should be done. If union has occured, then a valgus osteotomy is advised.

- Septic arthritis : knee fusion.

- Peroneal nerve injury : prevention : careful attention during insertion of the wire which must go through the fibular head. If injury has occured : decompression of the nerve, release of the compressing fascia.

Results

Between January 1991 to December 1997, 56 patients with complex tibial plateau fractures were managed with percutaneous internal fixation and hybrid Ilizarov ring fixator. There were 47 men and 9 women, all were followed up for a minimum of 12 months (average 3 yrs.) Average age of patients : 39 years (range, 22-65 years.)

Eight patients had a Schatzker type 4, 22a type

5 and 26a type 6 fracture. Ten patients with open fractures were treated with immediate irrigation, debridement, and Figures.

Figures 8a & 8d

30 year old man, high energy trauma to right

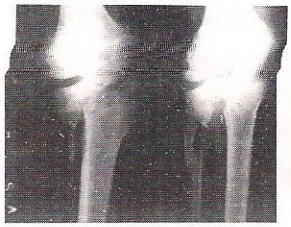

Figure 8a

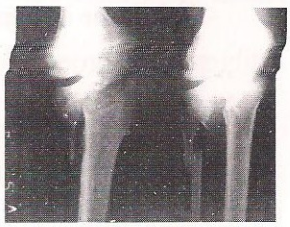

Figure 8b

Figure 8c

Figure 8d

knee due to motorcycle accident.

a) A P and oblique radiographs showong fracture subluxation with comminution and depression of lateral plateau.

b) A P radiograph of right hip shows a subtrochanteric fracture.

c) State after reduction and percutaneous fixation with cancellous bone screws. The frame extends to the femur. Small articular irregularities persist. Intramedullary nailing of the femoral fracture.

d) A P and lateral radiographs taken 6 months post injury. Evidence of union. The external fixateur had been removed 3 months after the injury.

Table 1

Soft tissue injury associated with fractures of the tibial plateau.

Type	Number of patients
Dislocation of knee with arterial injury	2
Meniscal injury	3
Ligamentous injury (medial collateral, *anterior cruciate)*	*8*
Peroneal nerve injury	3

temporary immobilization. After wound healing, definitive fixation was carried out. Associated soft tissue injuries were present in 16 patients (Table 1).

Most of the injuries were due to motor vehicle accidents. Four patients had fallen from a tree and four from a bullock cart. Ten patients had other major fractures, involving femur, ankle, or tibial shaft. Four patients showed a fracture of the tibial tuberosity requiring fixation.

Two patients had a knee dislocation with injury to the popliteal artery which was treated by bypass grafting. Both patients wrer treated initially with AO monolateral fixator, then changed to an Ilizarov fixator after soft tissue healing, One had to undergo above knee amputation because of uncontrolled, servere infection. The Ilizarov external fixtor was applied within 24-72 h in 40 patients. In the remaiing patients, the fixator was applied after a perioed of 1 week of elevation of the limb and soft tissue care.

48 patients had an acceptable reduction by longitudinal traction alone on a fracture table. An articular surface incongruity of less that 3 mm. was judged to be a satisfactory reduction. In four instances, depressed fragments were approached through a cortical window and elevated using an impactor (Figure 8).

In ten patients with open fractures, an extension into the knee joint was seen twice. An arthroscopically assisted reduction was never performed.

Firuges 9a to 9c

Figure 9a

40 years old man, traffic accident, injury to both tibiae, compound fracture of righ tibial plateau. Tratement with internal fixation using percutaneous lag screw and ilizarov external fixateru.



Figure 9b

a) A P and lateral radiographs after removal of lag screw and ilizrov fixator.

b) A P and lateral radiographs taken after arthrodesis stabilized with an ilizarov fixator.

Figure 9c

c) A P and lateral radiograpohs showing successful fusion. The external fixateur had been removed 3 months postoperatively.

Figure 10a

Figure 10b



Figure 10c

Figure 10d

Figures 10 a to 10d

45 year old man, fall from a ladder, fracture of tibial plateau of left knee.

a) A P and lateral readiographs showing the comminution and depression of the lateral tibial plateau.

b) Oblique readiographs show subluxation, comminution, and depression of the lateral plateau.

c) A P and lateral radiographs after reduction and internal fixation and application of ilizarov fixator. Note the presence of two olive wires.

d) A P and lateral readiographs taken after 1 year. The external fixateur had been removed after 4 months. Evidence of union. There is a varus deformity of 10°.

Figures 11a to 11d

60 year old man, fall from motor bike, fracture of tibial plateau of left knee.

a) A P and lateral radiographs show a bicondylar fracture. Cominution and depression of lateral plateau.

Figure 11a

b) Oblique X-Ray of the same knee.

Figure 11b

c) A P and lateral X-Rays taken after reduction and percutaneous fixation, Compression of the fracture was achieved with cancellous screw. The frame was extended to the femur.

Figure 11c

d) A P and lateral readiographs taken 4 months after injury. Evidence of union. The frame had been removed after 3 months.

Figure 11d

All patients achieved fracture union after a mean of 14 weeks (range, 12-18 weeks). one patient had septic arthritis, which needed fusion of the knee followed by reapplication of the Ilizarov apparatus. This patient had suffered an open fracture (Firuge 9).

Six patients showed 5-10° of vaurs, one patient 15° of vaurs (Figue 10). In four patients, a fixed flexion deformity varying between 5 and 10° was observed. Five patients had limitation of flexion between 20 and 90°. Three patients showed an extension lag between 10-30°. in three patients, sereve pin track infection necessitated a curettage, 20 patients had a monor pin trck infection which healed after antibiotic treatment. Four patients needed an autogenous bone graft at the metaphyseodiaphyseal junction. Eight patients suffered associated ligamentous injuries. Their frame was extended to the femur. Articular incongruity of the tibial plateau averaged 3 mm. (range, 0-5 mm) postoperatively (Figure 11).

Using the score of the American Knee Society [7], an excellent result was obtained in 20 patients, a good result in 28, a fair result in four, and a poor result in four patients.

References

1. Apley A. Fractures of the lateral tibial condyle treated by skeletal traction and early mobilization. J. Bone Joint Surg Br. 1956;38:699-708.

2. Apley AG. Fractures of the tibial plateau. Orthop Clin North Am 1979;10:61-74.

3. Christensen K, Powell J, Bucholz R, Stills M. Early results of combined internal-external fixation of treatment of high grade tibial plateau fractures. J Orthop Trauma 1990;4:266. abstract.

4. Dendrinos GK, Kontos S, Katsenis D, Dalas A. Treatment of high energy tibial plateau fractures by the ilizarov circular fixateau. J. Bone Joint Surg Br. 1996;78:710-7.

5. Green SA. Pin and wire technique for external fixation. Instr Course Lect 1995:44:487-93.

6. Hohl M. Complications of tibial plateau fractures. In:Epps CH Jr, ed. Complications in orthopedic surgery, 3rd end. Philadelphia: Lippincott, 1994:543.

7.. Insall JN, Dorr LD, Scott RD, Scott WN. Rationale of the Knee Society clinical rating system. Clin Orthop 1989;248:13-4.

8. Schatzkar J. Compression in the surgical treatment of fractures of the tibia. Clin Orthop 1974;105:220-9.